Nouvelles entités de tumeur de rein non inclus dans l'OMS

Eva COMPERAT

Service d'Anatomie et Cytologie Pathologique

Hôpital Tenon, Sorbonne University, Paris

SORBONNE UNIVERSITÉ
CRÉATEURS DE FUTURS DEPUIS 1257

GRC-N°5

Hôpitaux Universitaires Est Parisien
TENON

Renal cell tumours

Clear cell renal cell carcinoma	8310/3
Multilocular cystic renal neoplasm of low malignant potential	8316/1
Papillary renal cell carcinoma	8255/1
Hereditary leiomyomatosis and renal cell carcinoma (HLRCC)-associated renal cell carcinoma	8311/3*
Chromophobe renal cell carcinoma	8317/3
Collecting duct carcinoma	8319/3
Renal medullary carcinoma	8510/3
MiT Family translocation carcinomas	8311/3
Succinate dehydrogenase (SDH)-deficient renal carcinoma	8312/3
Mucinous tubular and spindle cell carcinoma	8480/3
Tubulocystic renal cell carcinoma	8316/3
Acquired cystic disease associated renal cell carcinoma	8316/3
Clear cell papillary renal cell carcinoma	8323/1
Renal cell carcinoma, unclassified	8312/3
Papillary adenoma	8260/0
Oncocytoma	8290/0

1975→2 entités, 2004 → 50 entités
2016→55 entités, 202X→ +???

Me
Me
Me
Me

Ne
Nephrogenic rests
Nephroblastoma 8960/3
Cystic partially differentiated nephroblastoma 8959/1
Paediatric cystic nephroma 8959/0

Mesenchymal tumours

Mesenchymal tumours occurring mainly in children

Clear cell sarcoma	8964/3
Rhabdoid tumour	8963/3
Congenital mesoblastic nephroma	8960/1
Ossifying renal tumour of infants	8967/0

Mesenchymal tumours occurring mainly in adults

Leiomyosarcoma	8890/3
Angiosarcoma	9120/3
Rhabdomyosarcoma	8900/3
Osteosarcoma	9180/3
Synovial sarcoma	9040/3
Ewing sarcoma / Peripheral neuroectodermal tumour	9260/3
Angiomyolipoma	8860/0
Epithelioid angiomyolipoma	8860/1
Leiomyoma	8890/0
Haemangioma	9120/0
Lymphangioma	9170/0
Haemangioblastoma	9161/1
Juxtaglomerular cell tumour	8361/0
Renomedullary interstitial cell tumour	8966/0
Schwannoma	9560/0
Solitary fibrous tumour	8815/1

Mixed epithelial and mesenchymal tumours

Cystic nephroma	8959/0
Mixed epithelial and stromal tumour	8959/0

Miscellaneous tumours
Renal haematopoietic neoplasms
Germ cell tumours

Metastatic tumours

The morphology codes are from the International Classification of Diseases for Oncology (ICD-O) {917A}. Behaviour is coded /0 for benign tumours; /1 for unspecified, borderline, or uncertain behaviour; /2 for carcinoma in situ and grade III intraepithelial neoplasia; and /3 for malignant tumours. The classification is modified from the previous WHO classification {756A}, taking into account changes in our understanding of these lesions.
* These new codes were approved by the IARC/WHO Committee for ICD-O.

nouvelles propositions

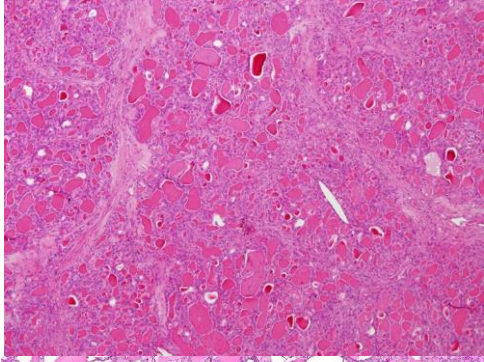

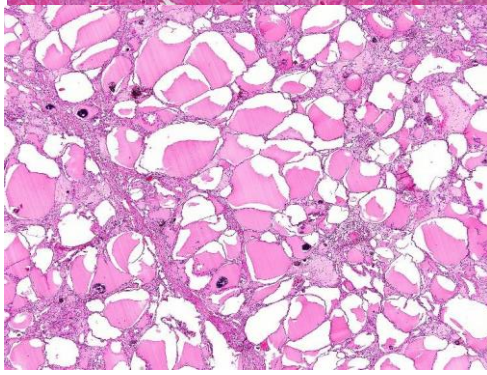

- thyroid-like follicular
- atrophic kidney like RCC
- ALK positive RCC
  - micropapillary pattern
  - mucin producing
- **eosinophilic solid and cystic RCC**
- **biphasic squamoid papillary RCC**
- low grade /high grade oncocytic (LOT/HOT)tumors
- Whartin-like RCC
- papillary carcinoma with reversed polarity

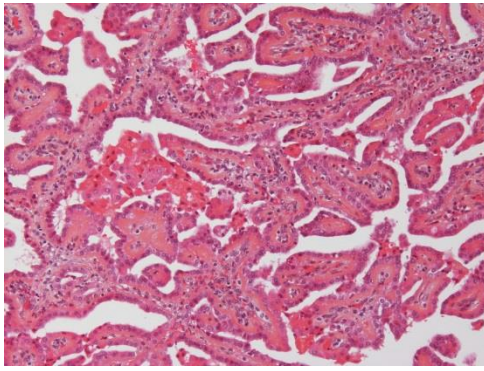

LOT (low grade oncocytic)

- CK7+/CD117-
- AE1/3, E-cad, PAX8+
- Hale luminal
- pas de capsule

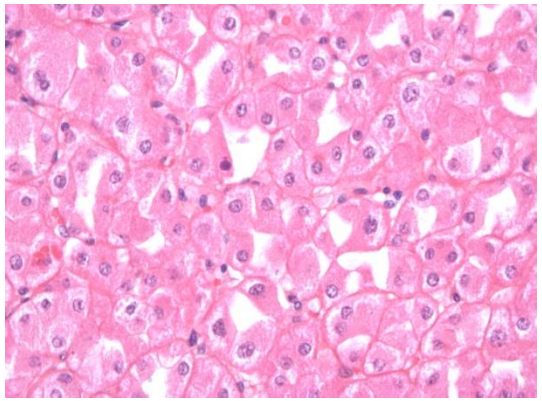

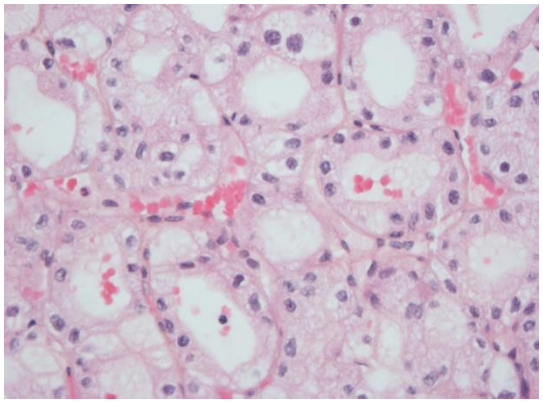

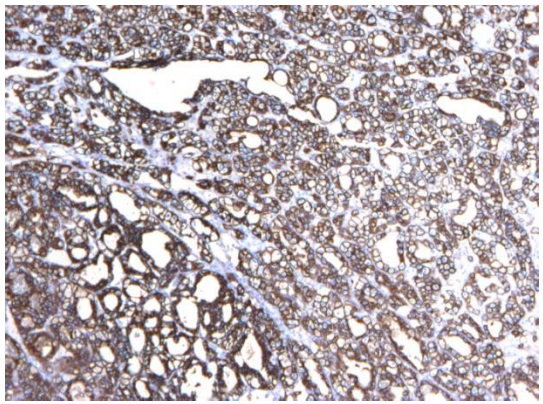

HOT (high grade oncocytic tumors)

- caractéristiques histologiques
  - membranes cytoplasmiques ++
  - vacuoles intracytoplasmiques
  - vaisseaux épais
  - noyaux de grande taille
  - nucléoles proéminents
- 93% cathepsine + et CD10+
- 64% CD117+
- CK7 – ou focal (oncocytome)
- AE1/AE3+
- PAX8+

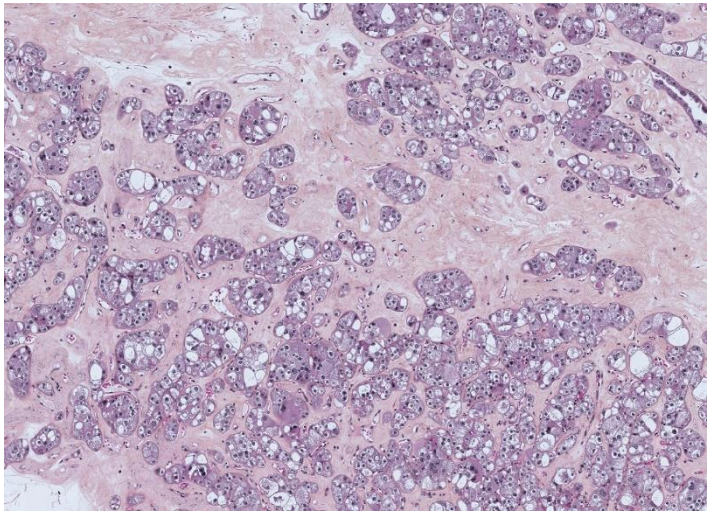

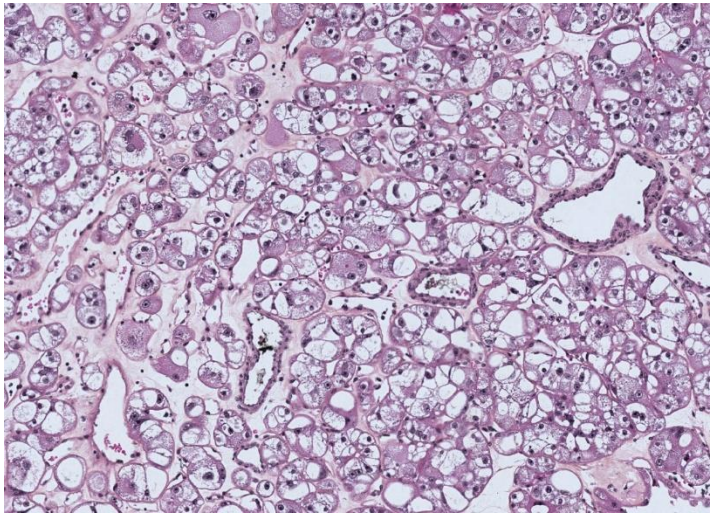

part 1

ESC (eosinophilic solid and cystic RCC)

Parilla AJSP 2018

Trpkov AJSP 2016

Dr Kruslin

ESC

Pas encore dans l'OMS 2016

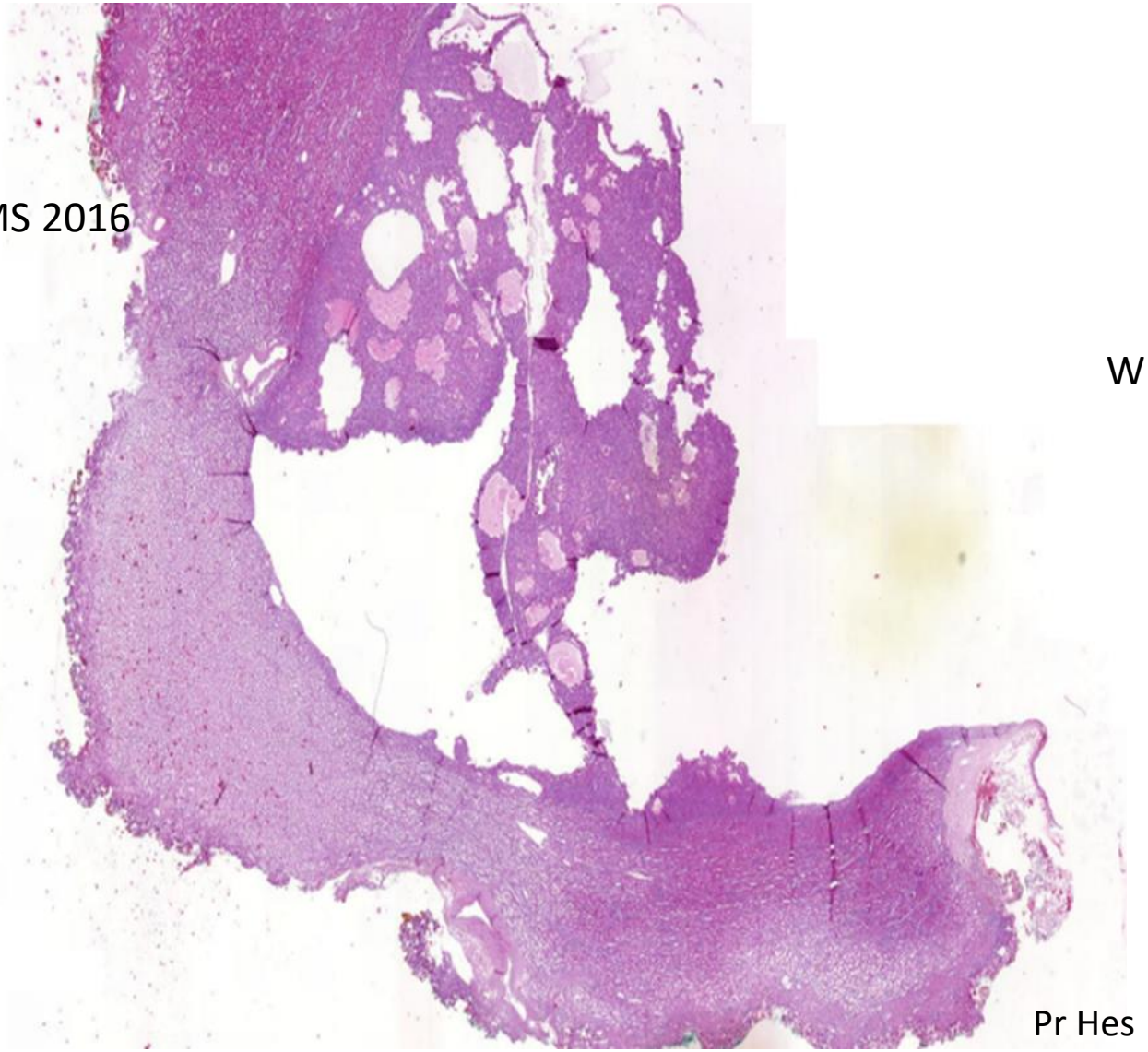

WHO 2016

Pr Hes

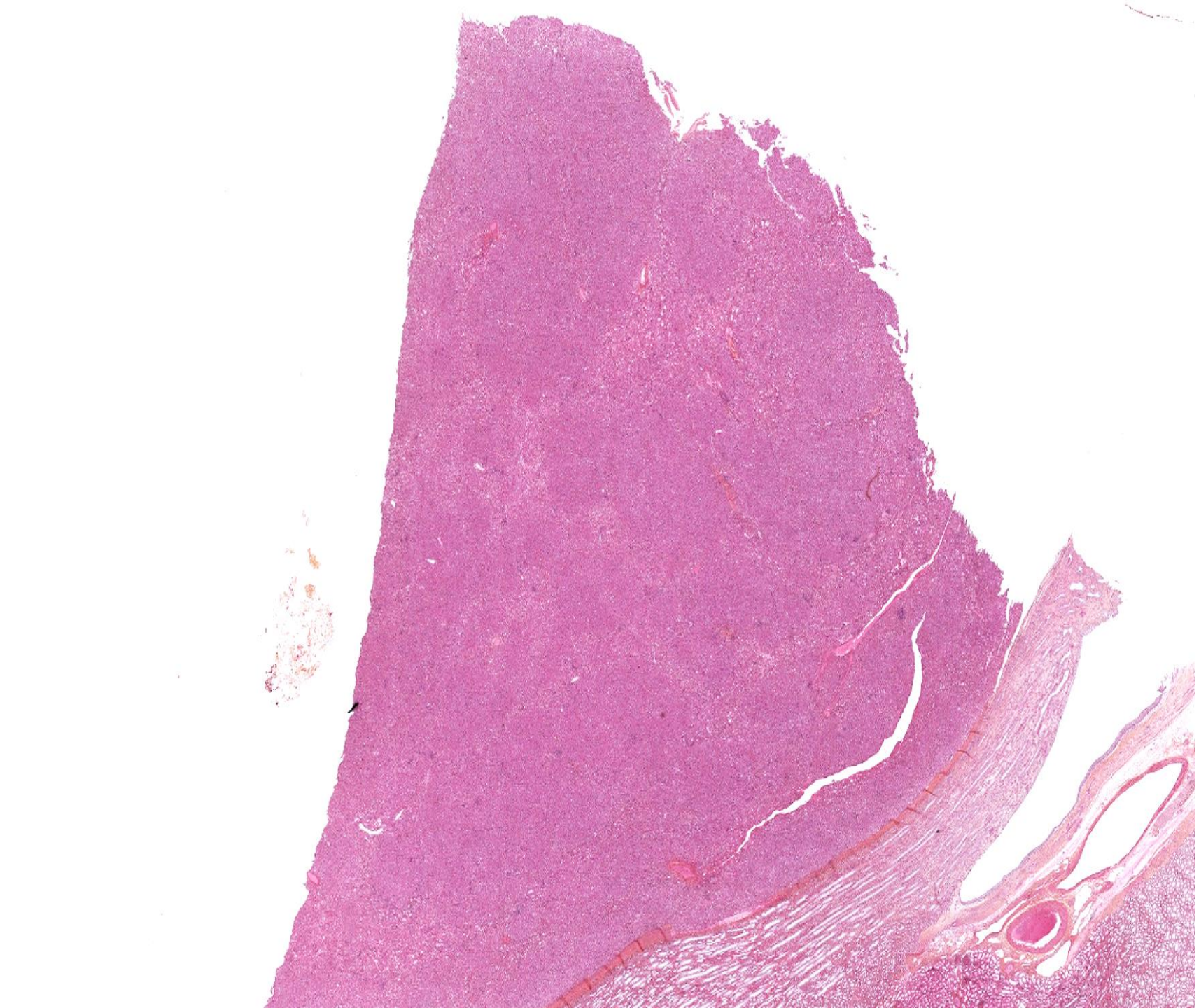

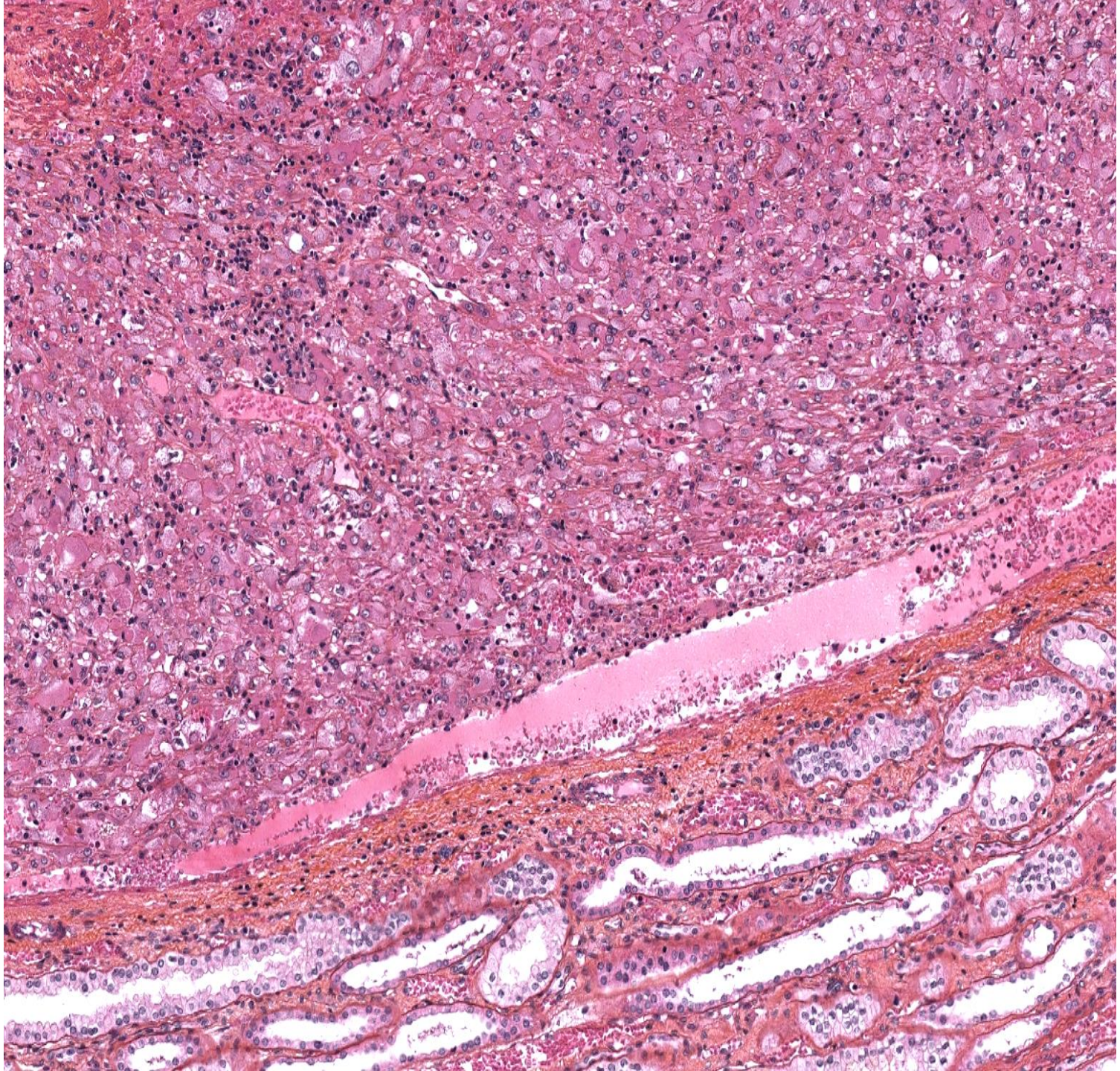

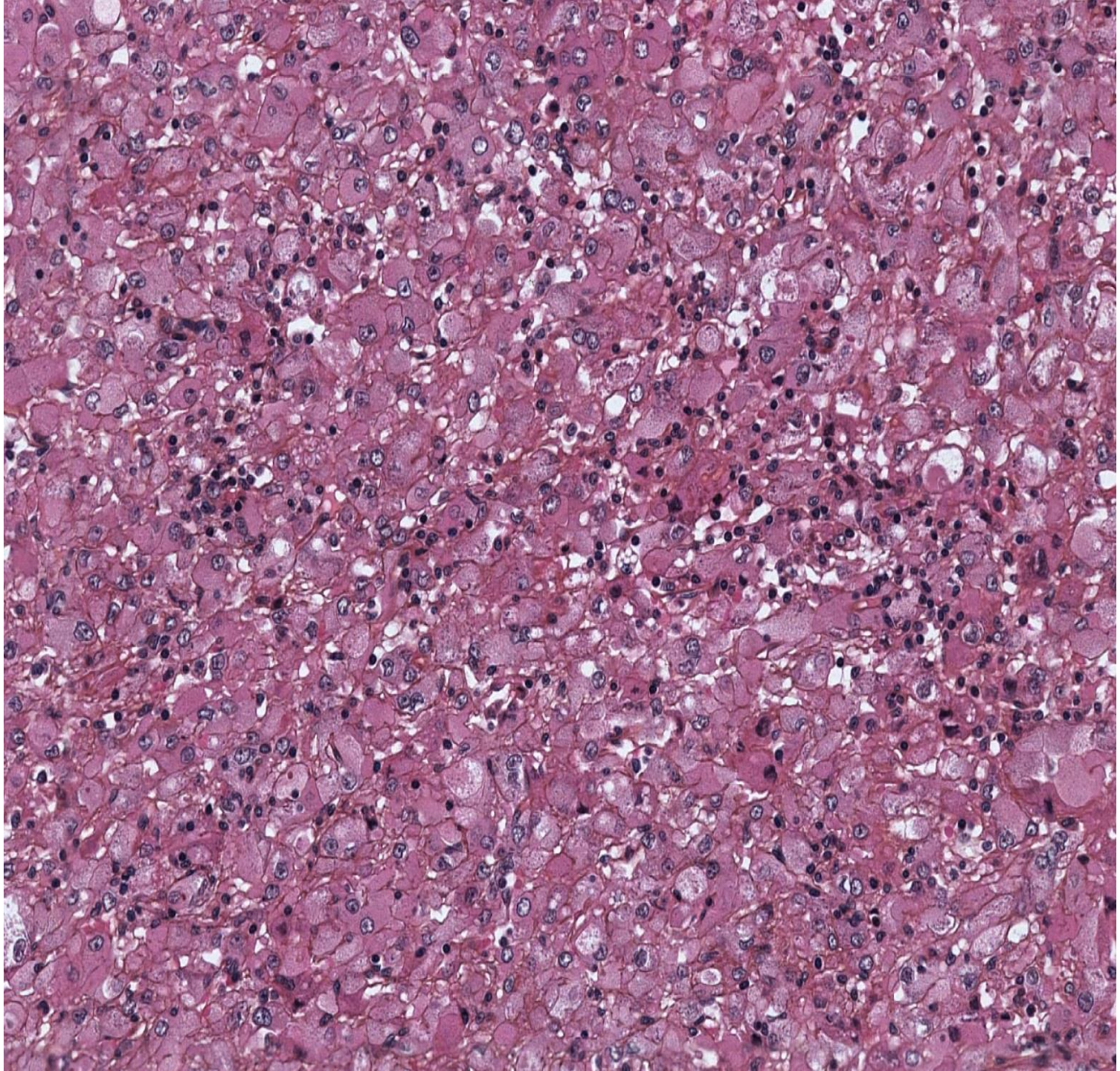

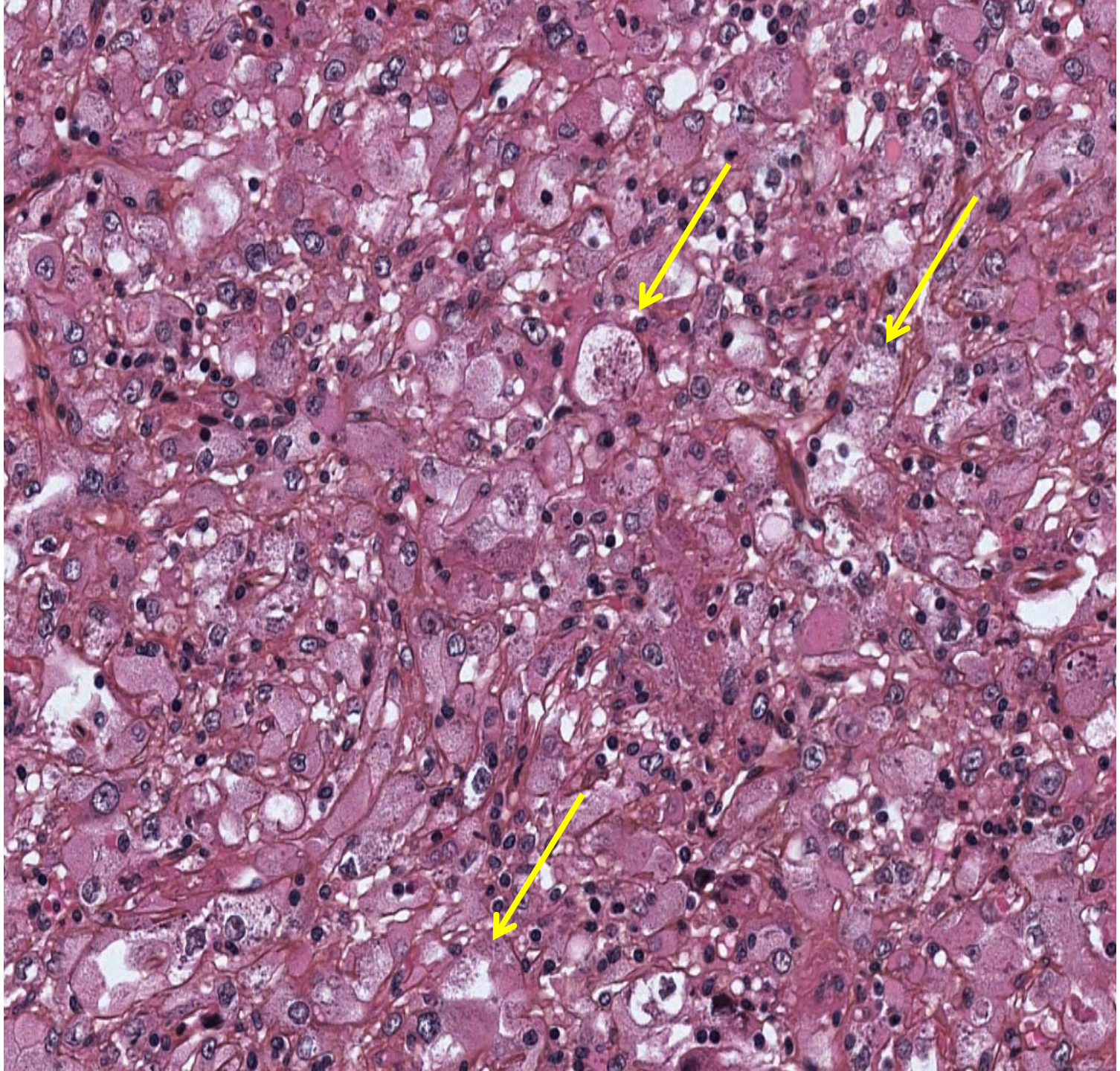

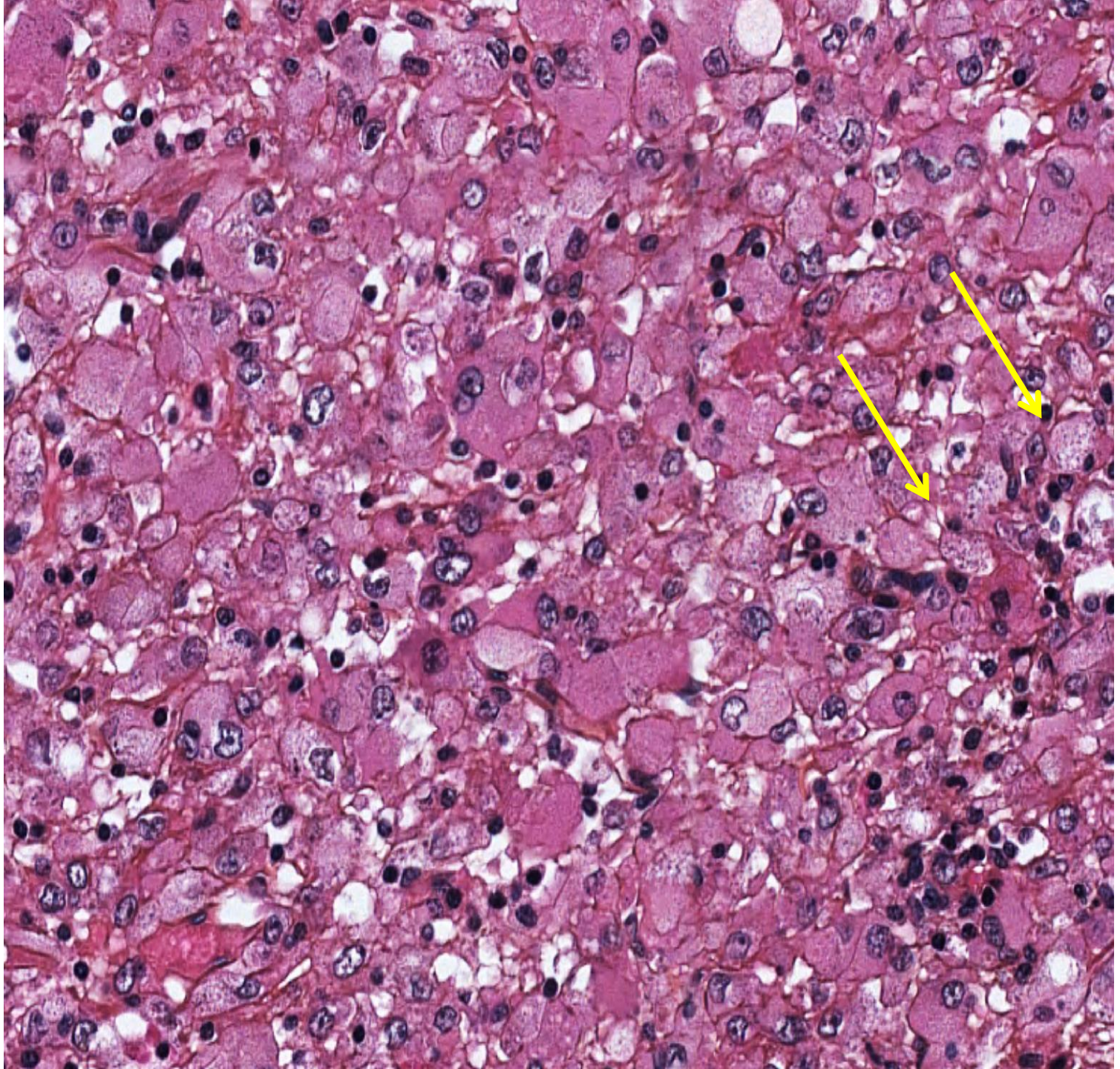

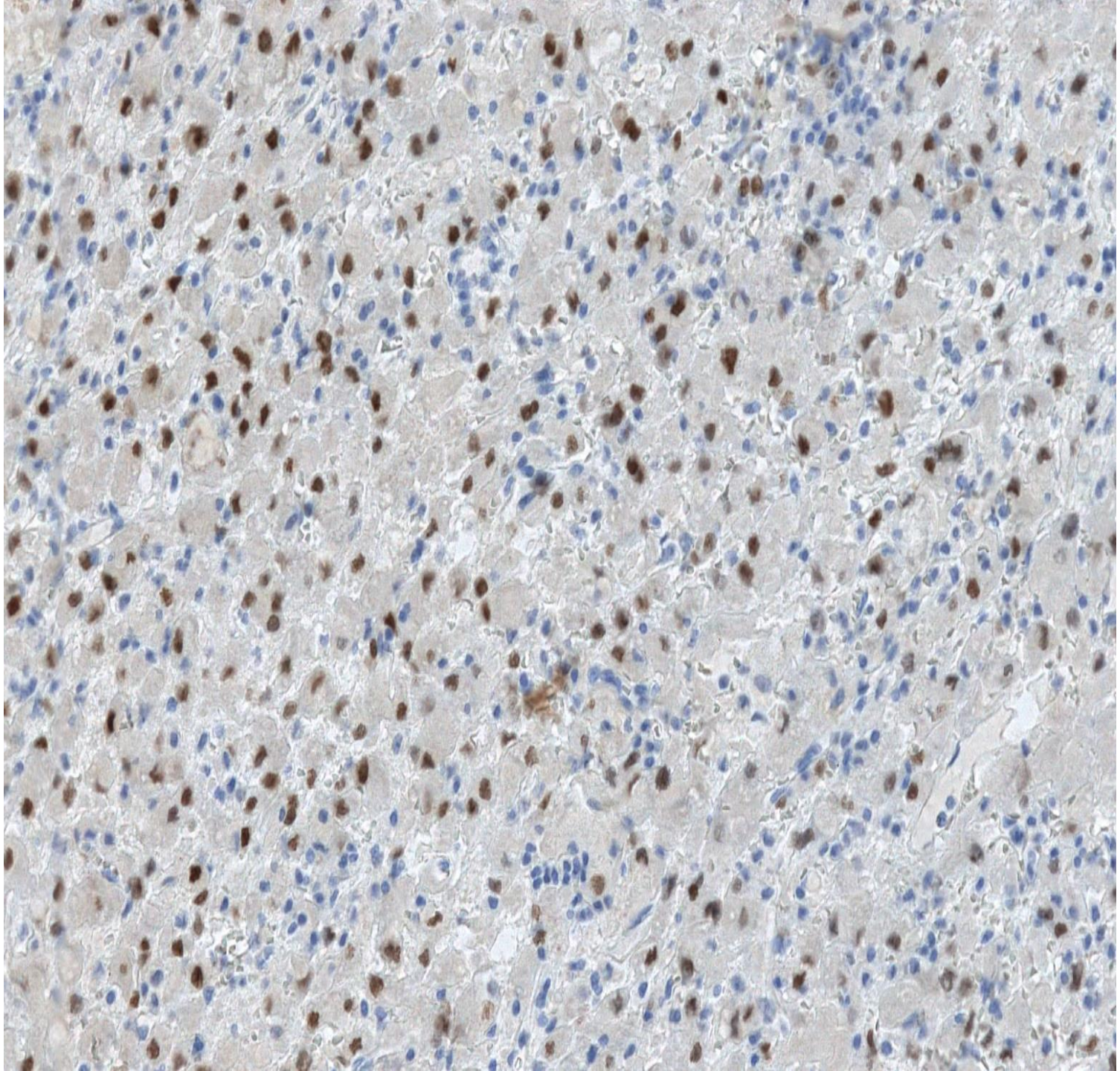

PAX8

ESC

- dans 2 circonstances
- lié à STB
- sporadique

Distinctive Morphology of Renal Cell Carcinomas in Tuberous Sclerosis

Andrew Schreiner, MD,[1] Siamak Daneshmand, MD,[2]
Aaron Bayne, MD,[2] Gayle Countryman, BS,[1]
Christopher L. Corless, MD, PhD,[1]
and Megan L. Troxell, MD, PhD[1]

- Homme 43 ans
- STB connu
- 4 tumeurs
- multiples kystes
- HMB45-, AML –

- DD: AML épithélioïde
- fréquent dans STB

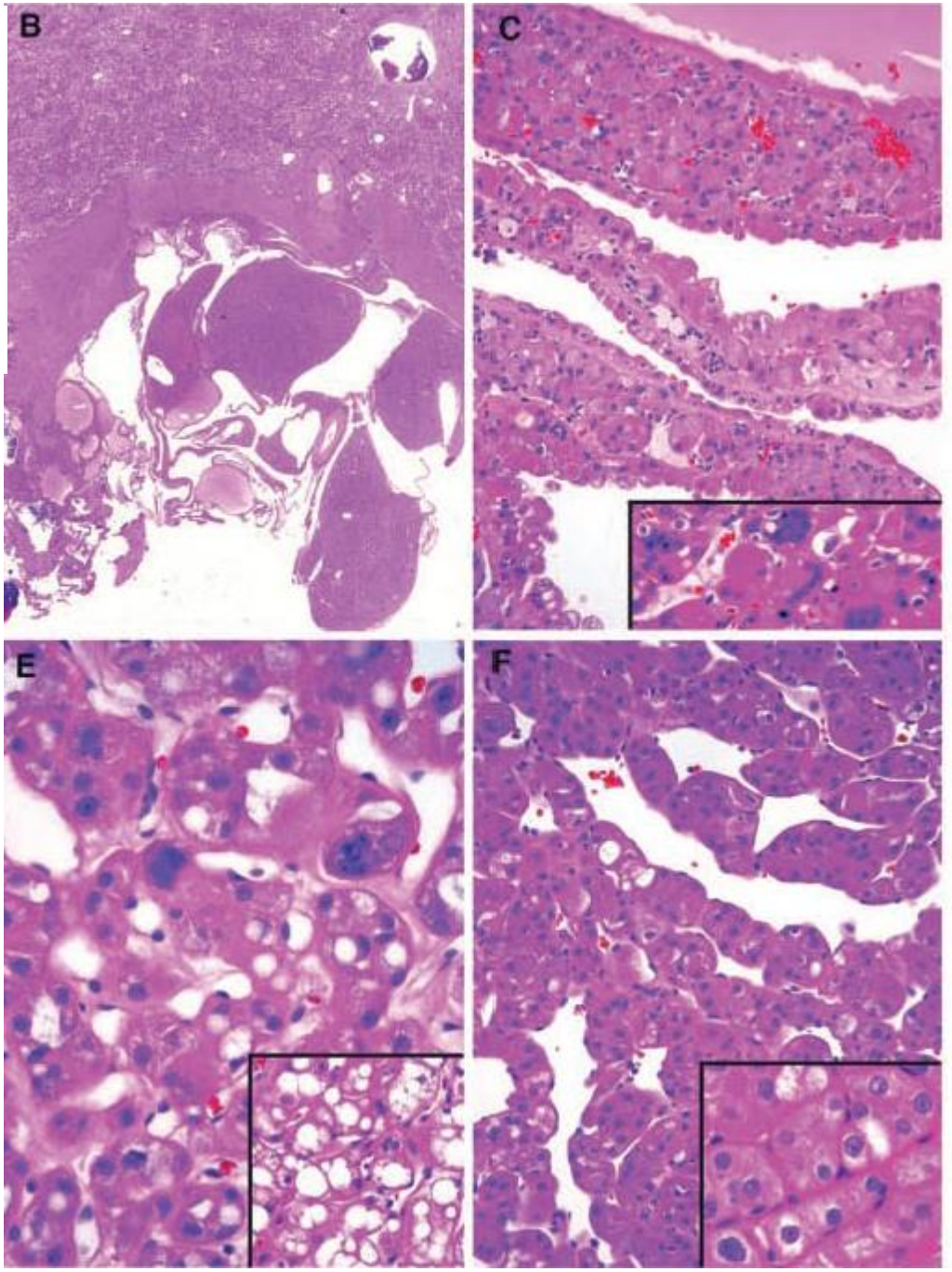

Int J Surg Pathol 2010

STB

- autosomal dominant
  - *TSC1* et *2*
- prédominance féminine
- tumeurs AML (80%) et AML épithelioïde-like
- kystes épithéliaux
- tumeurs rénales multiples et bilatérales
  - autres organes également touchés
  - pénétrance variable
  - 60-70% nouveaux cas sporadiques
  - sans histoire familiale
- survie bonne, indolent

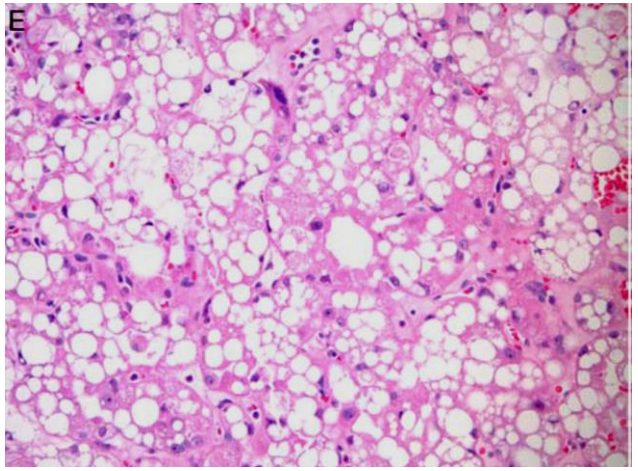

Tuberous Sclerosis–associated Renal Cell Carcinoma

A Clinicopathologic Study of 57 Separate Carcinomas in 18 Patients

Juan Guo, MD, PhD, Maria S. Tretiakova, MD, PhD,† Megan L. Troxell, MD, PhD,‡ Adeboye O. Osunkoya, MD,§ Oluwole Fadare, MD,‖ Ankur R. Sangoi, MD,¶ Steven S. Shen, MD, PhD,# Antonio Lopez-Beltran, MD, PhD,** Rohit Mehra, MD,†† Amer Heider, MD,†† John P. Higgins, MD,‡‡ Lara R. Harik, MD,§§ Xavier Leroy, MD,‖‖ Anthony J. Gill, MD,¶¶ Kiril Trpkov, MD,## Steven C. Campbell, MD, PhD,*** Christopher Przybycin, MD,**** Cristina Magi-Galluzzi, MD, PhD,**** and Jesse K. McKenney, MD*****

- ressemblance avec carcinome chromophobe
- ESC

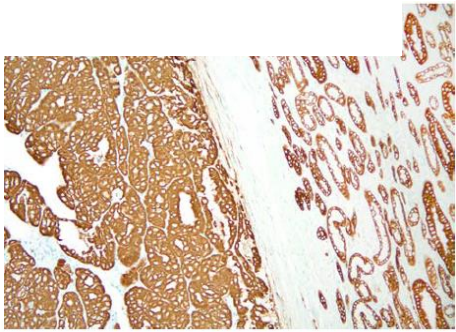

TABLE 2. Histologic and Immunophenotypic Findings

Histologic Pattern	# RCCs (n [%])	# Patients (n [%])*	PAX8	HMB45	CK7	CA9	CD117
RAT-like	17 (30)	7 (39)	8/8	0/8	8/8	8/8	0/5
Chromophobe-like	34 (59)	8 (44)	7/7	0/7	6/7	0/7	1/6
Eosinophilic/macrocystic	6 (11)	6 (33)	4/4	0/3	2/4	0/2	0/4

*Number of patients with at least 1 RCC of a given histologic pattern.
RAT-like indicates RCC resembling RAT/RCC with smooth muscle stroma.

ESC

- aussi cas sporadiques
- seulement femmes
  - hommes exception
- surtout pT1
  - taille 3,8-13,5cm
- pas agressives mais
  - ISUP grade 3

Schneider 2010 Int J Surg Pathol; Guo 2014, AJSP

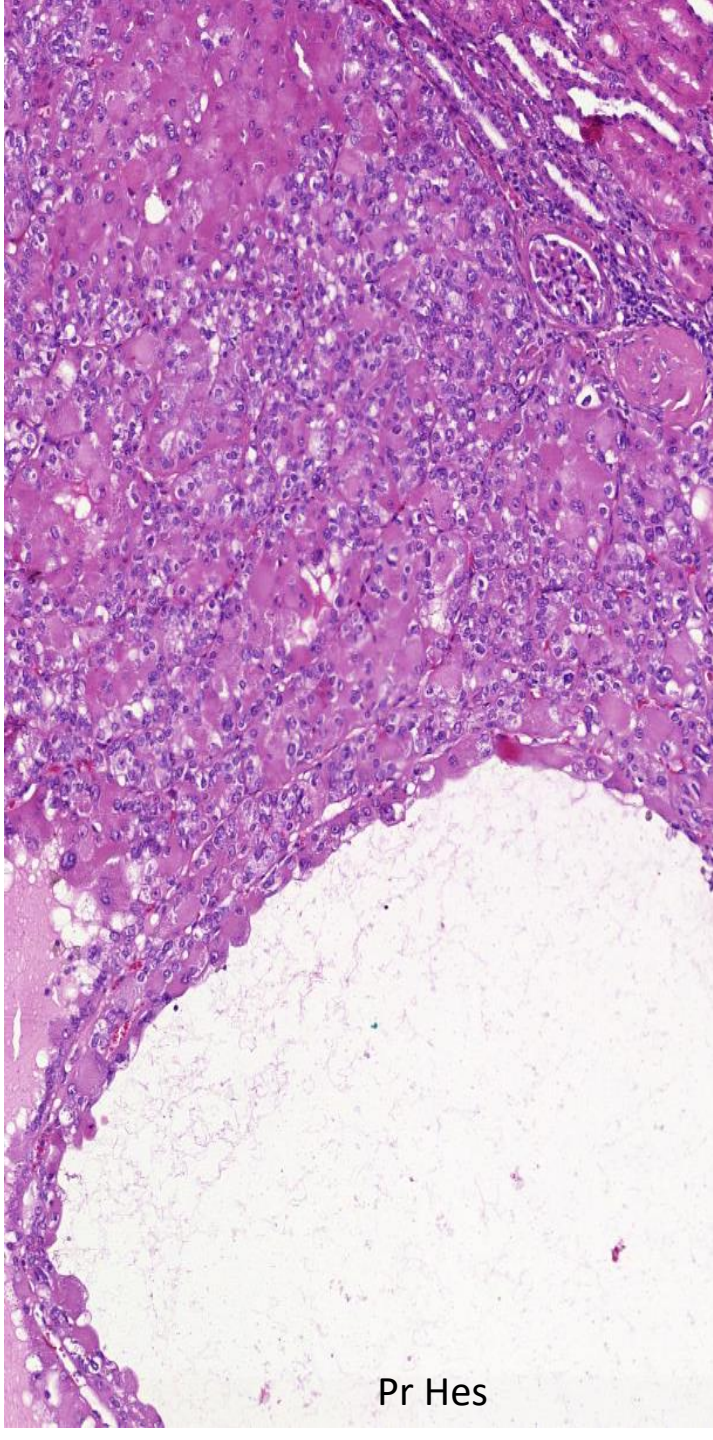

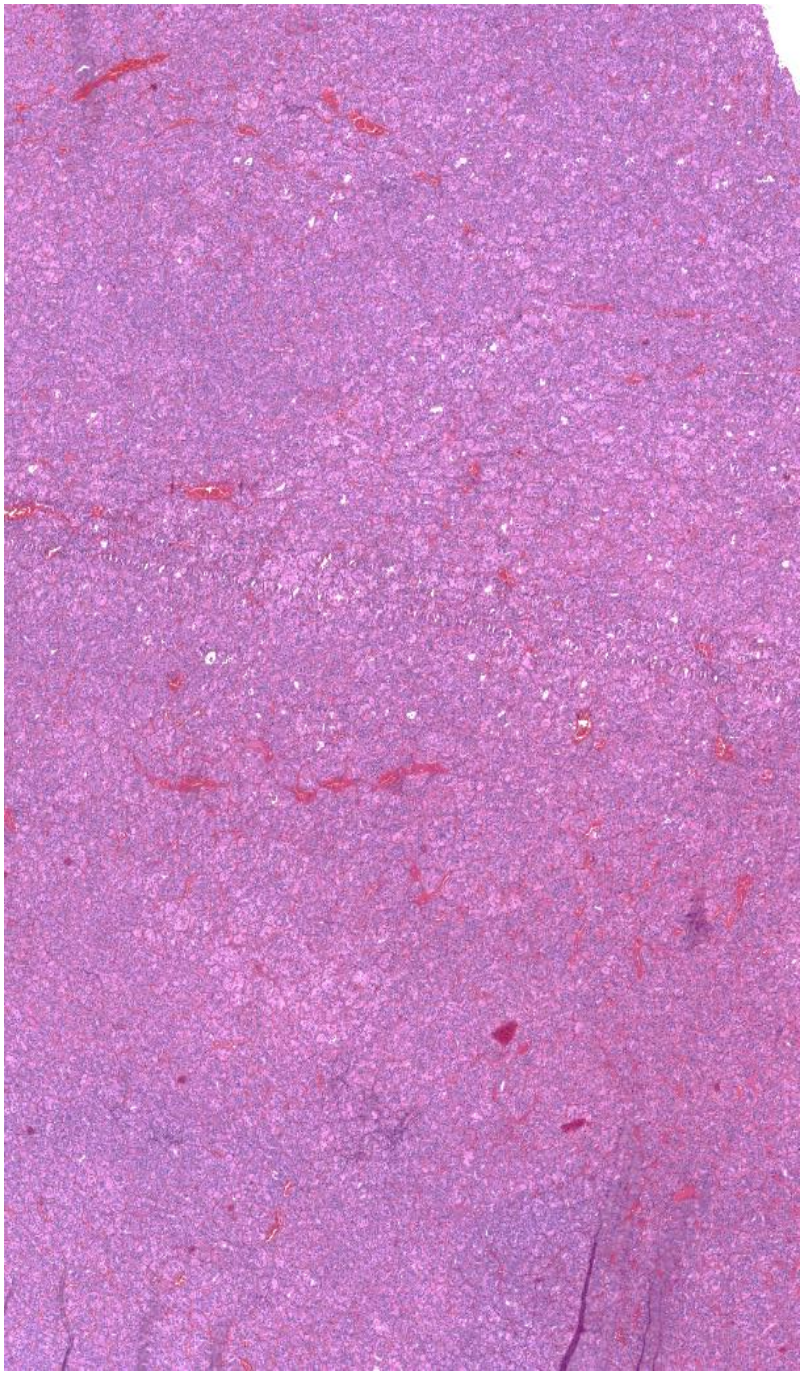

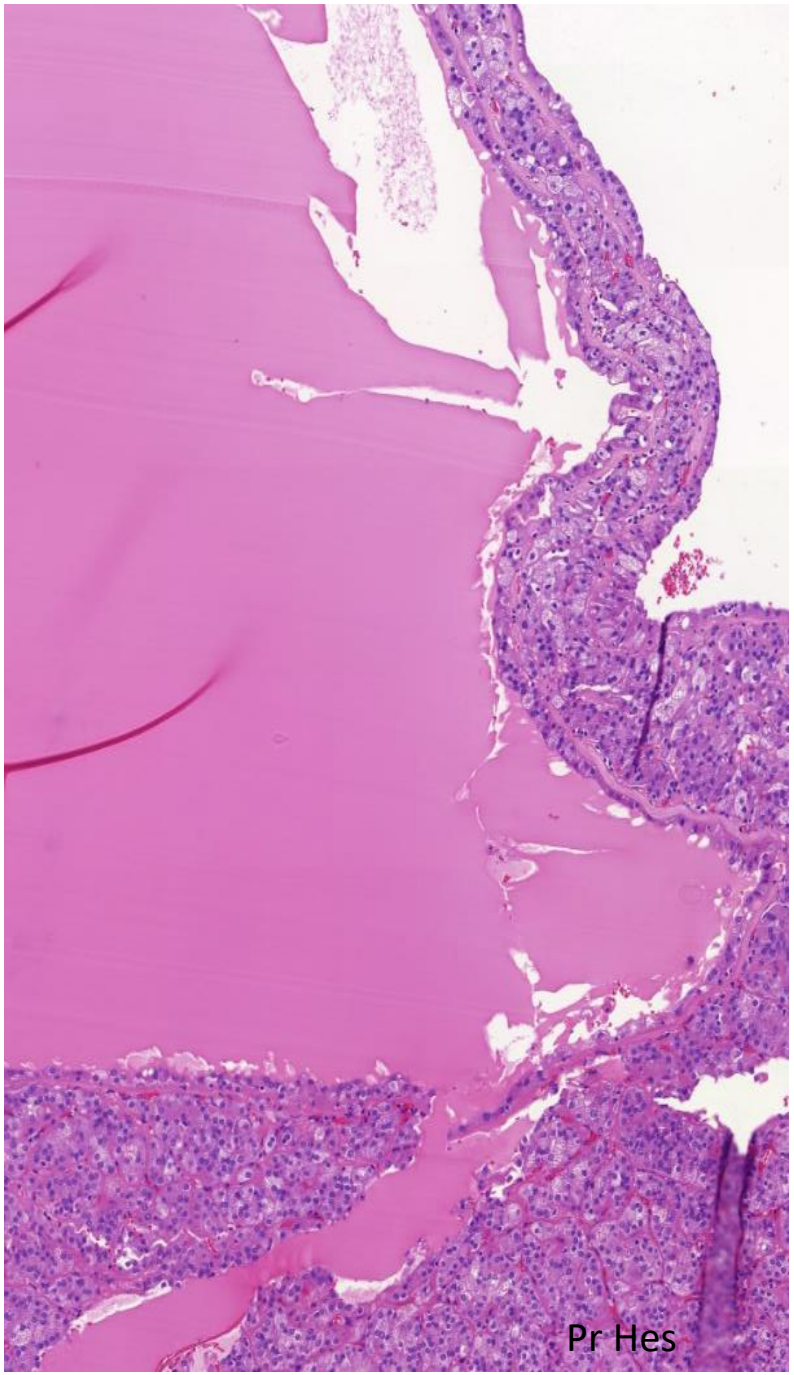
Pr Hes

ESC

- femmes, âge moyenne 57 ans (31-75)
- unifocal si sporadique
- à priori bénin
  - mais 4 cas M+
- incidence?
  - souvent appelé « inclassé » ou inclassé avec morphologie éosinophile/oncocytaire
  - 0,2%?
  - 10% dans STB

Li, Bioinformatics 2009

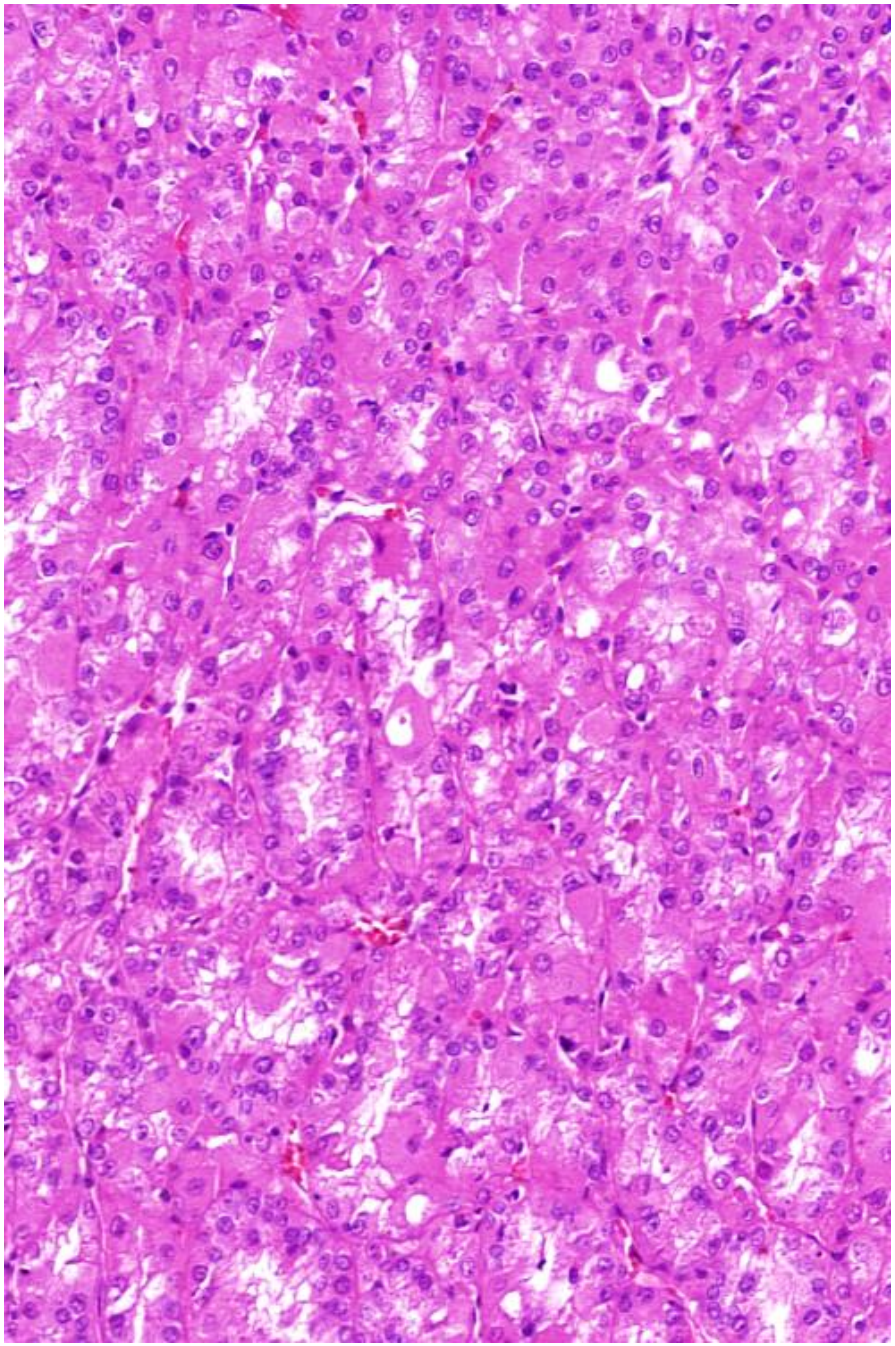

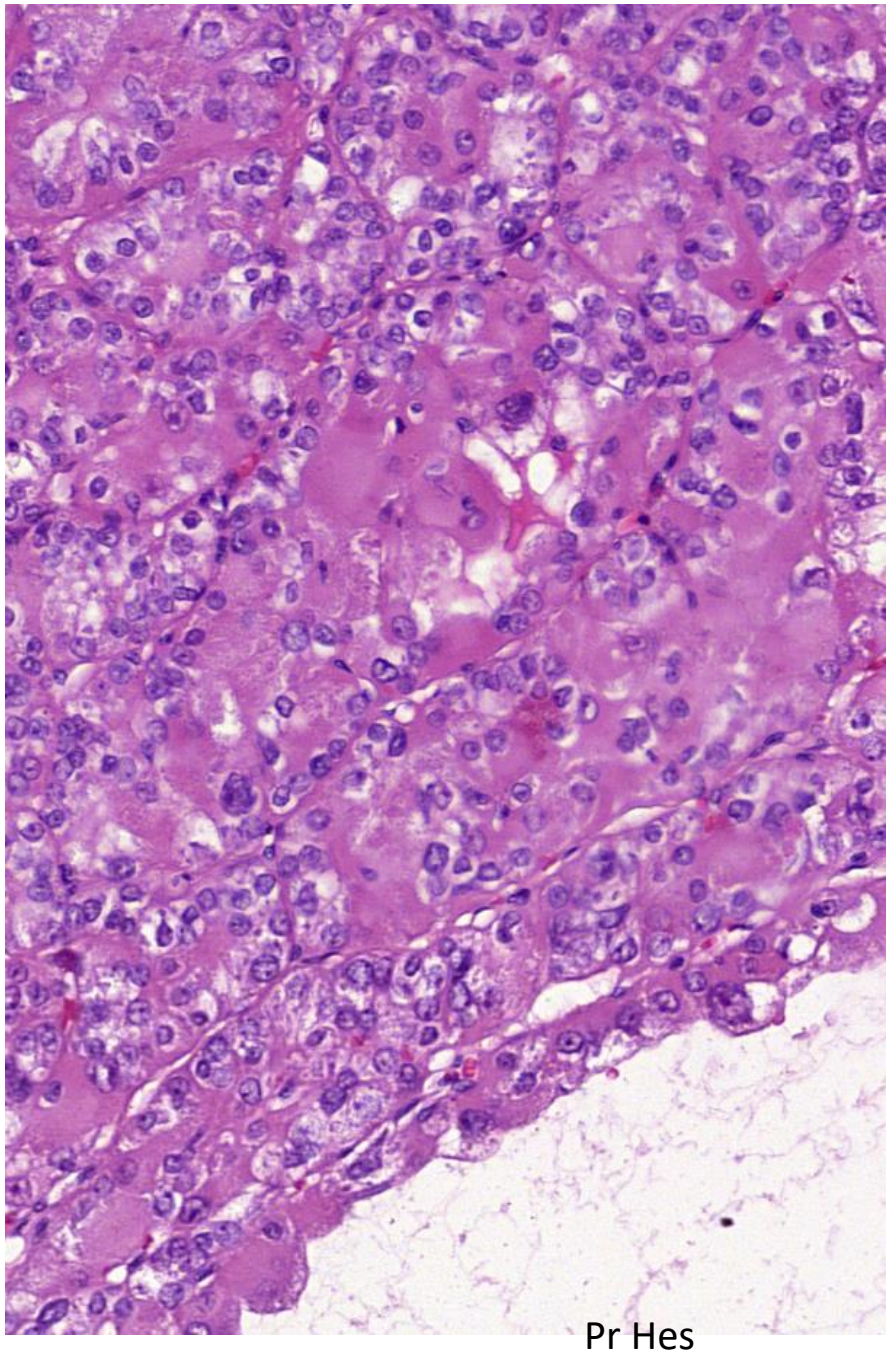

Pr Hes

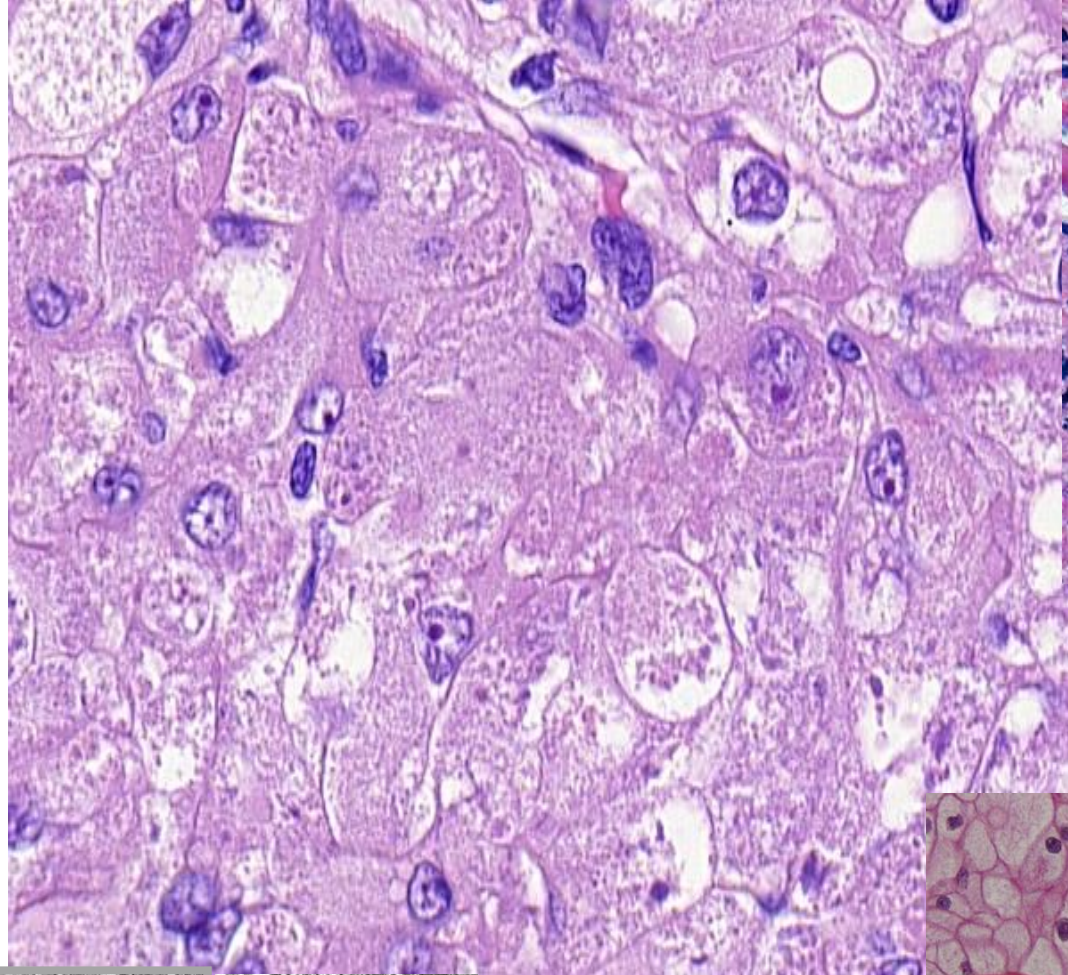

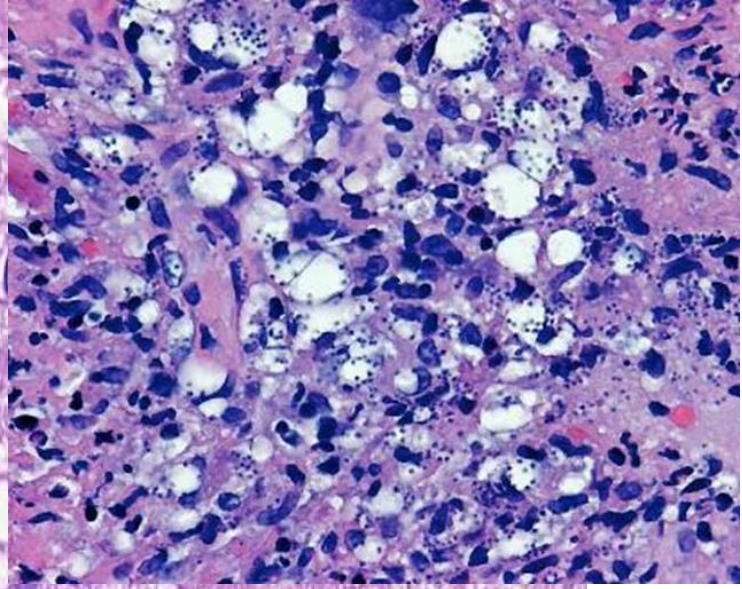

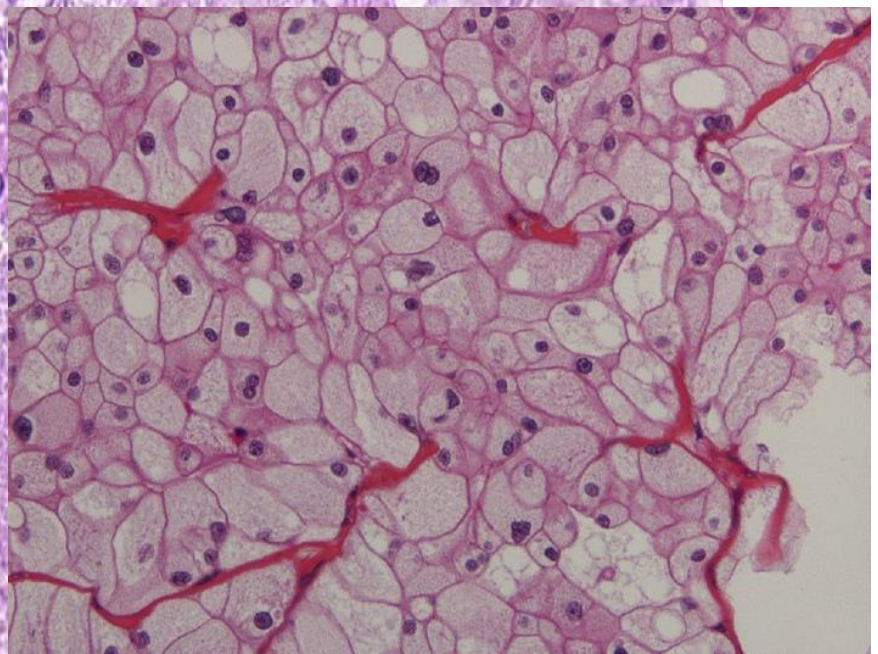

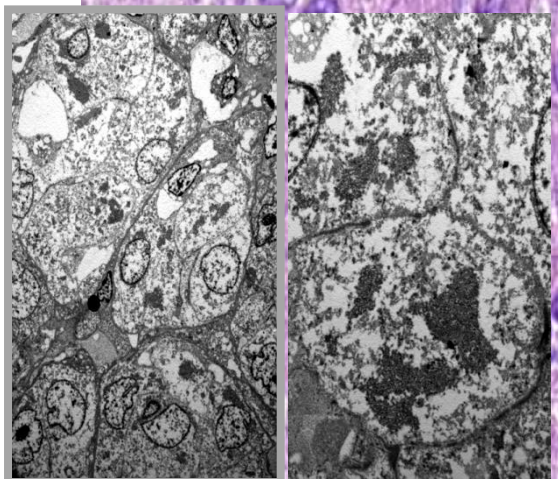

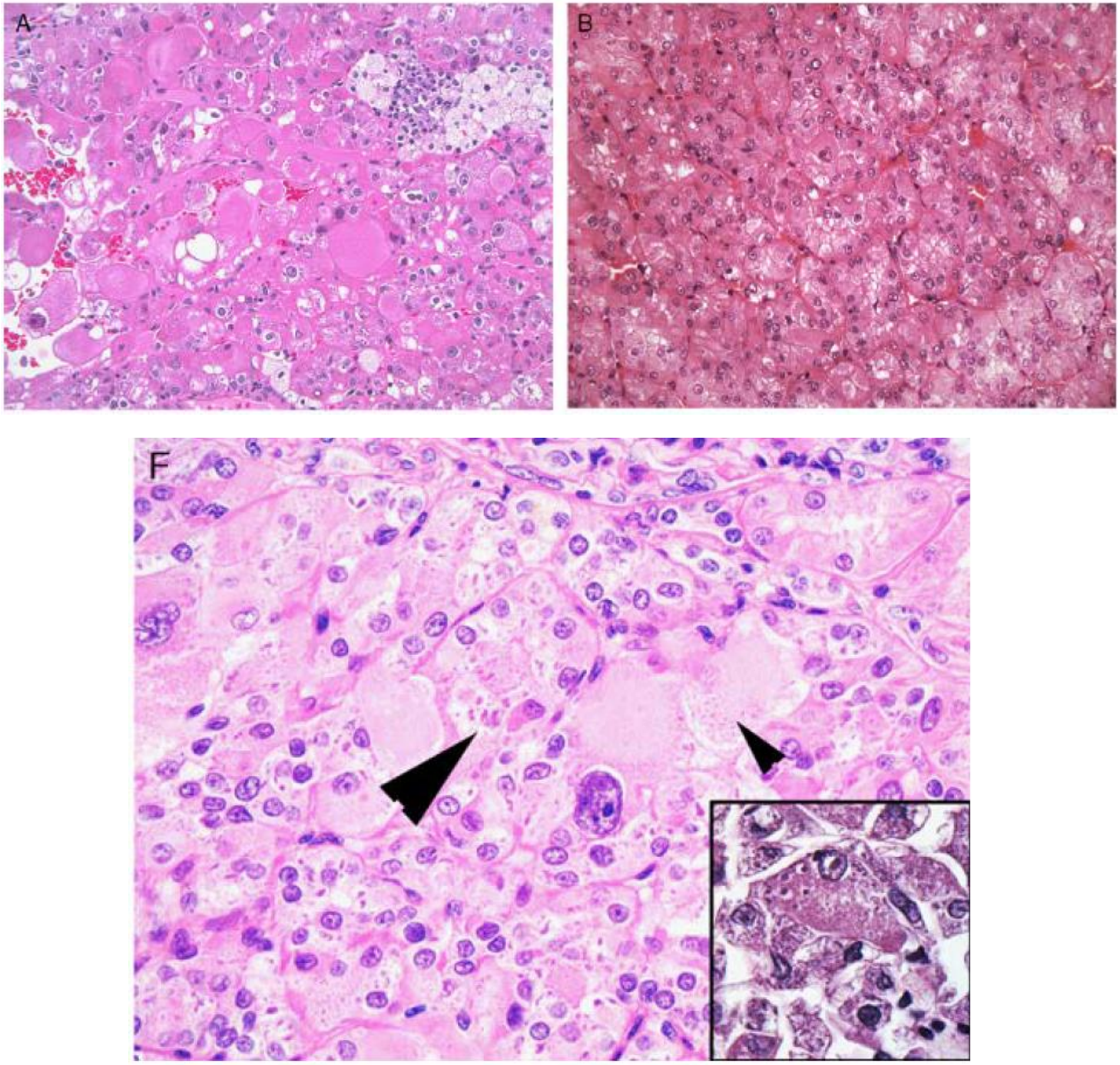
A
B
F

IHC et génétique

- PAX 8, **CK 20+**
- vimentine, p504s, CD10 +/-
- CK 7 – ou focalement +, CA 9, CD117, HMB45-
- tuberin +, hamartin –

- LOH: 16p, Xq, 11p
- gains: 1p, 7p-q, 10q, 13q, 16p-q
- perte: 19p, 11q, Xp, Xq

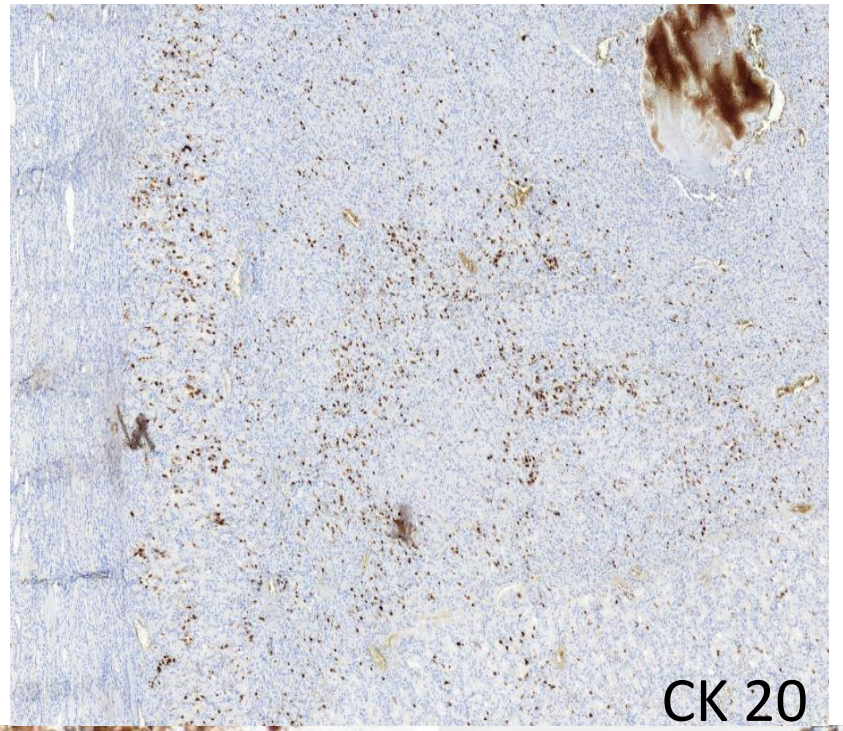

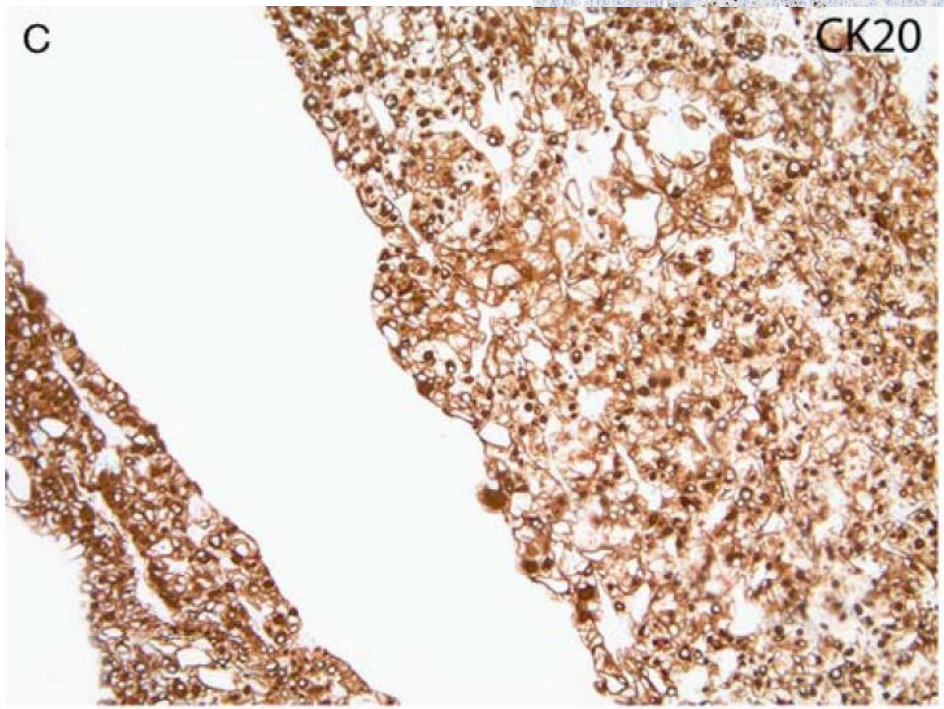

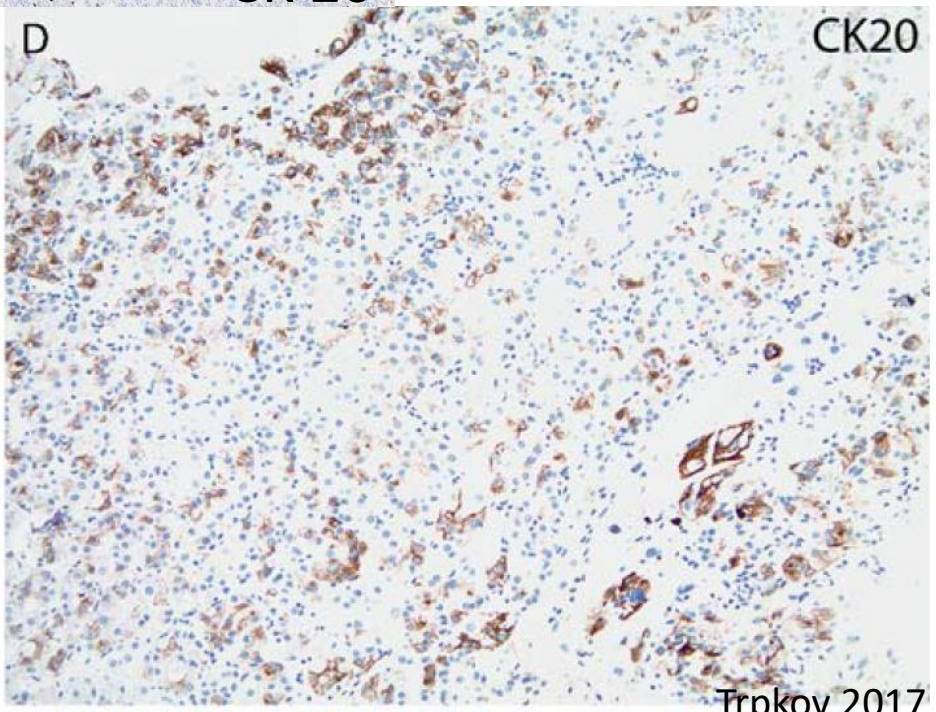

Trpkov 2017

Eosinophilic Solid and Cystic (ESC) Renal Cell Carcinomas Harbor *TSC* Mutations

Molecular Analysis Supports an Expanding Clinicopathologic Spectrum

Doreen N. Palsgrove, MD, Yunjie Li, MD,* Christine A. Pratilas, MD,* Ming-Tseh Lin, MD, PhD,* Aparna Pallavajjalla, MS,* Christopher Gocke, MD,* Angelo M. De Marzo, MD, PhD,* Andres Matoso, MD,* George J. Netto, MD,*† Jonathan I. Epstein, MD,* and Pedram Argani, MD**

- STB tumeurs multifocales et H=F
- tout âge
- post-neuroblastome
- présence constante de TSC1/2 mutations

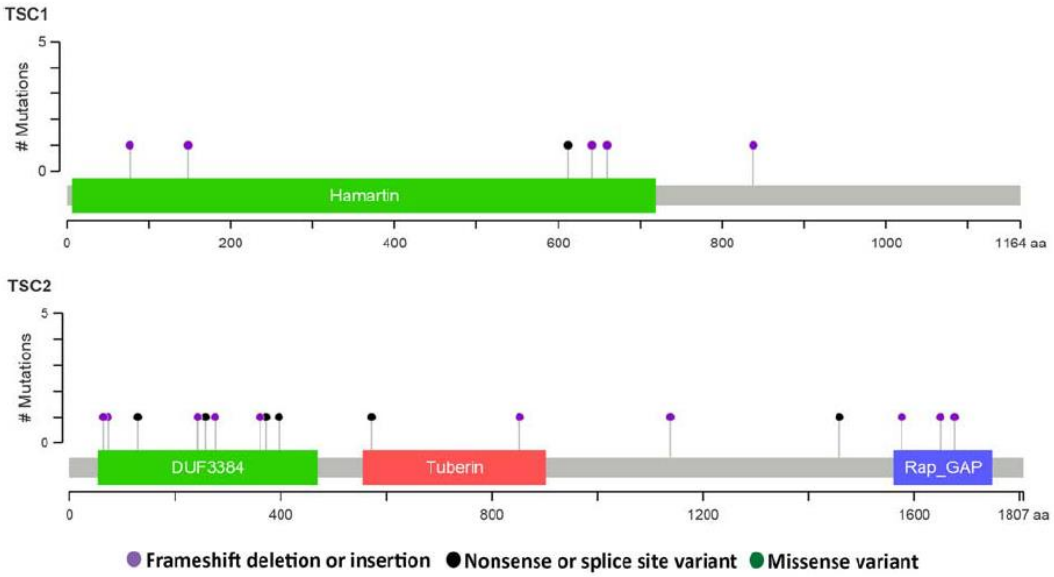

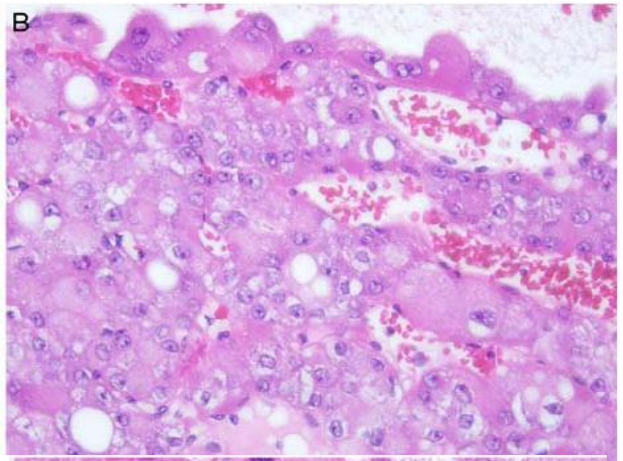

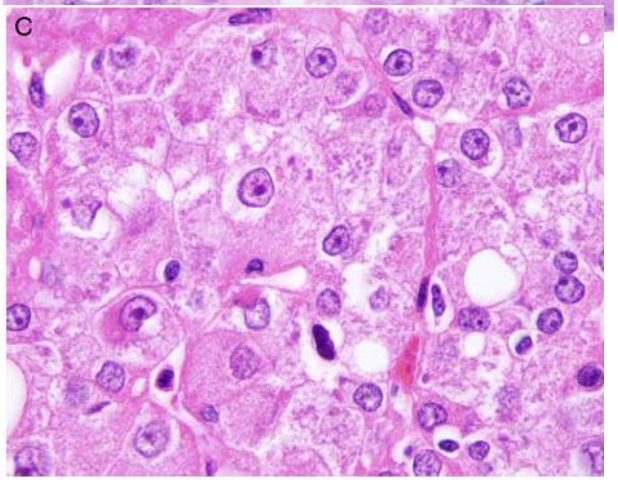

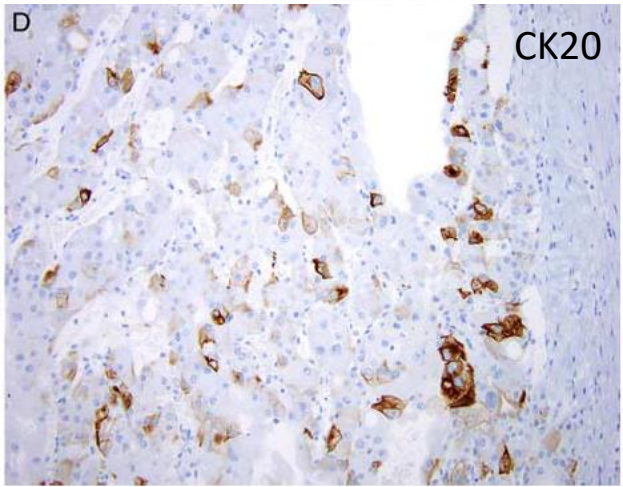

Are Sporadic Eosinophilic Solid and Cystic Renal Cell Carcinomas Characterized by Somatic Tuberous Sclerosis Gene Mutations?

Megan Parilla, MD, Sabah Kadri, PhD, Sushant A. Patil, PhD, Lauren Ritterhouse, MD, Jeremy Segal, MD, PhD, Kammi J. Henriksen, MD, and Tatjana Antic, MD

- 2 femmes sans STB
- lésions uniques
- altérations somatiques STB
  - dans cas sporadique
- m-Tor inhibiteurs si tumeur agressive?

TABLE 1. Genetic Variants Identified Including Variants of Uncertain Significance

Gene	Mutation Type	Coding Effect	Nucleotide Change
Mutations case 1			
BCOR	Substitution	Missense	NM_001123385.1:c.2423T>A
BRCA2	Substitution	Missense	NM_000059.3:c.175C>G
DNMT3A	Deletion	Frameshift	NM_022552.4:c.1171del
JAK2	Substitution	Missense	NM_004972.3:c.1849G>T
NOTCH2	Substitution	Missense	NM_024408.3:c.4973C>T
SMC1A	Substitution	Missense	NM_006306.3:c.2705A>G
TSC2	Substitution	Nonsense	NM_000548.4:c.1636G>T
TSC2	Substitution	Splicing	NM_000548.4:c.2356-1G>C
Mutations case 2			
ARID2	Substitution	Missense	NM_152641.3:c.3617C>T
BRCA2	Substitution	Missense	NM_000059.3:c.1798T>C
CEBPA	Duplication	In-frame	NM_004364.4:c.584_589dup
ERBB3	Substitution	Missense	NM_001982.3:c.3391G>A
MLH3	Substitution	Missense	NM_001040108.1:c.394G>A
TSC2	Substitution	Splicing	NM_000548.4:c.975+1G>T
TSC2	Deletion	In-frame	NM_000548.4:c.5238_5255del

AJSP 2018

DD

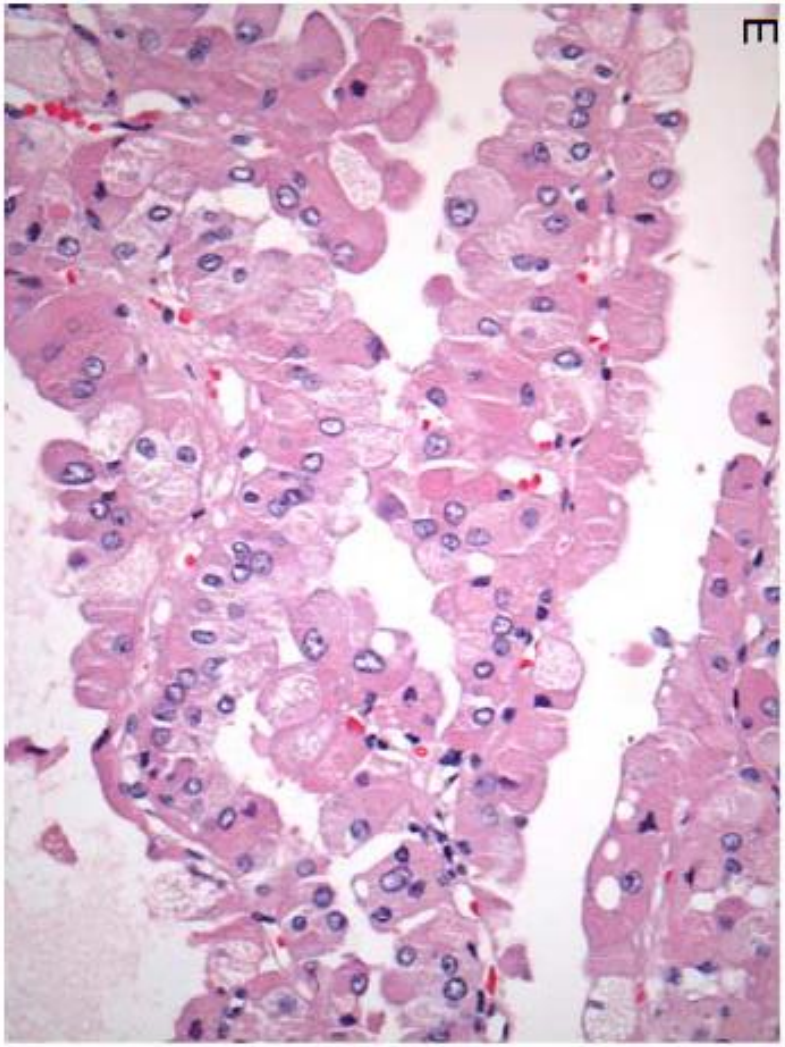

néoplasie multiloculaire

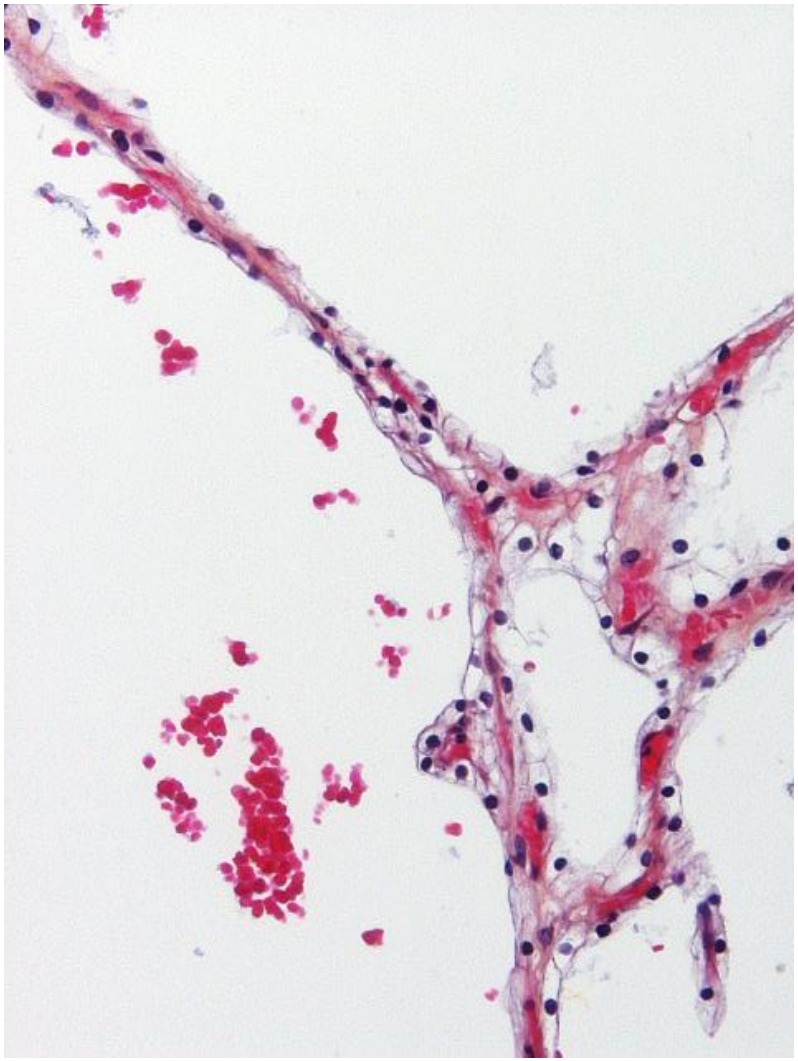

Trpkov2016 AJSP

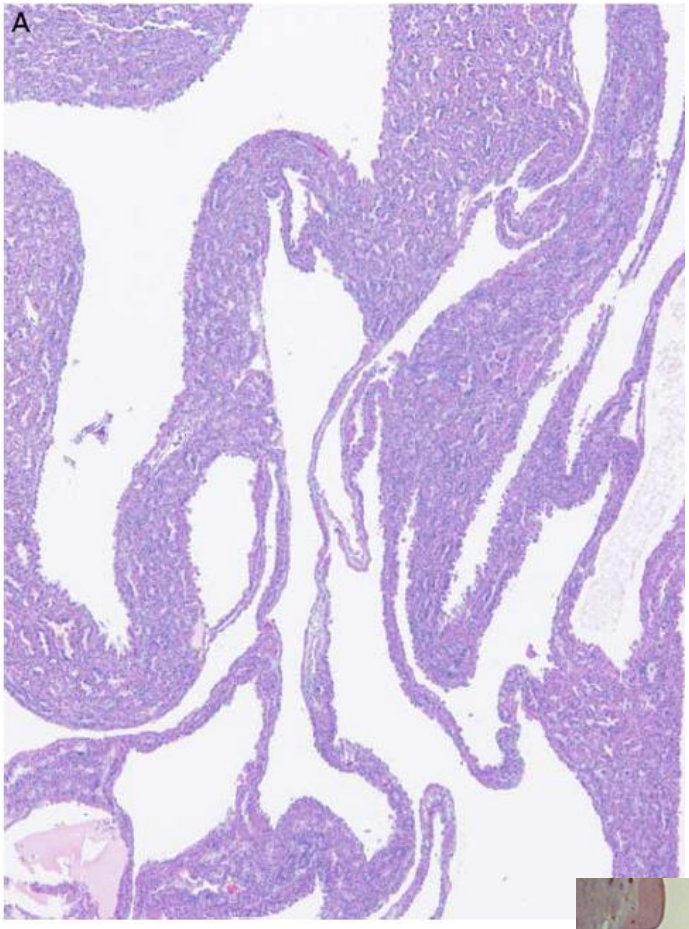

ESC

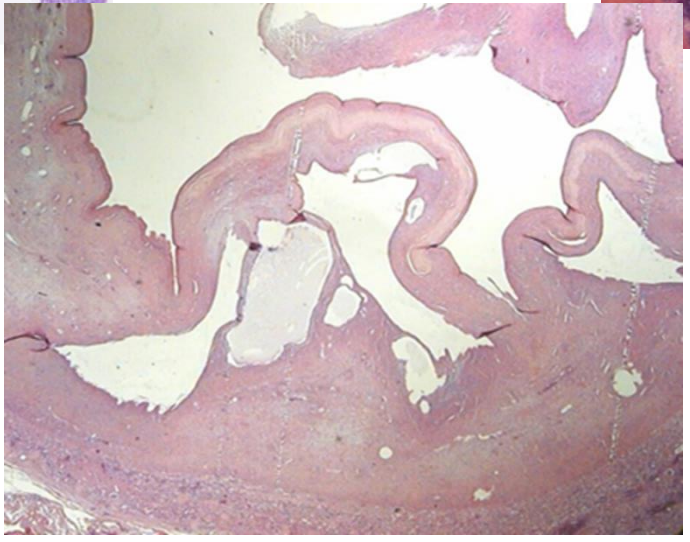

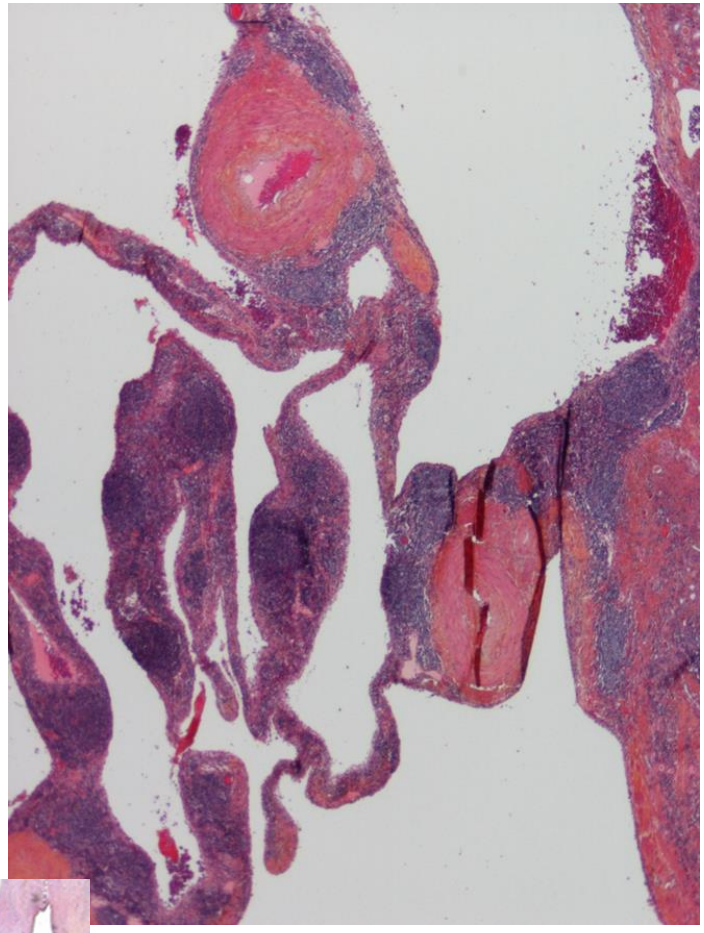

néphrome kystique

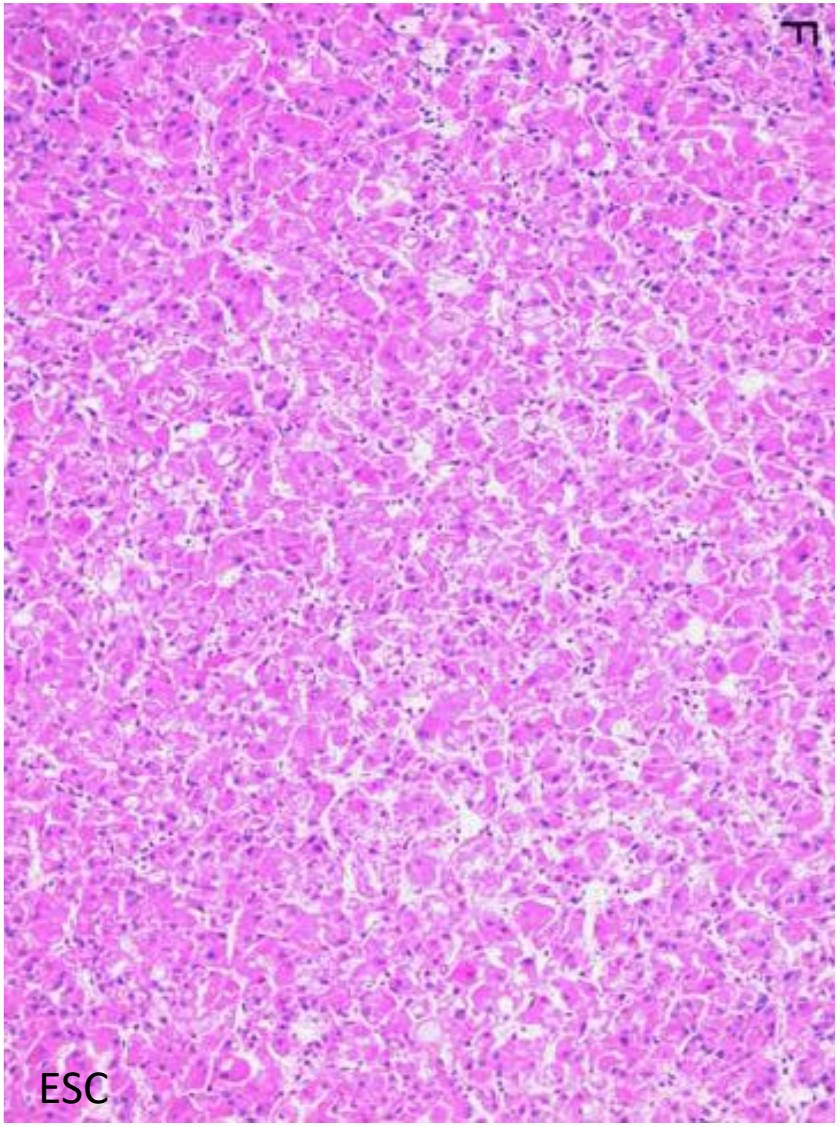
ESC

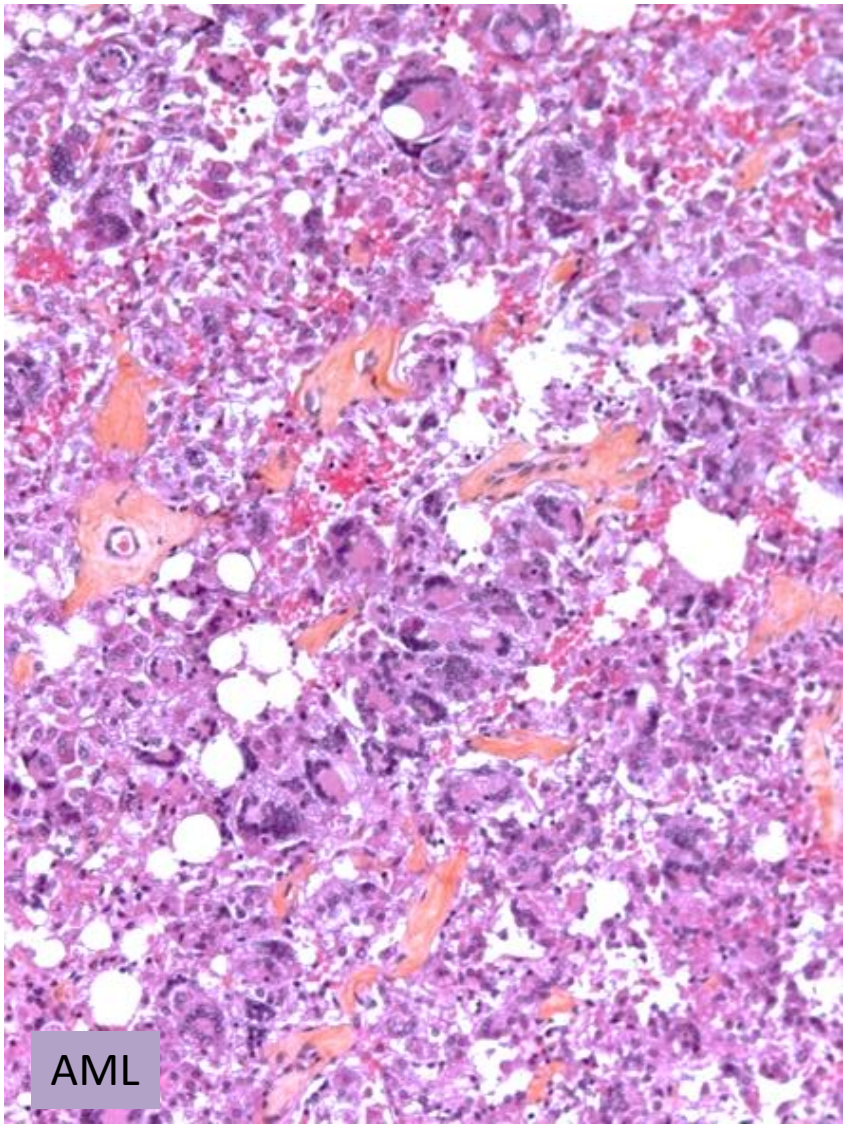
AML

TABLE 3. Key Features and Immunostains Helpful in Distinguishing ESC RCC From Other Renal Tumors

Diagnosis	Key Distinguishing Features	IHC
ESC RCC	Female individuals, solid and cystic growth, voluminous eosinophilic cytoplasm, granular cytoplasmic stippling, usually low stage	CK20$^+$/CK7$^-$, CD117$^-$, PAX8$^+$, PanCK$^+$, HMB45$^-$, CA9$^-$ (no membranous reactivity)
Chromophobe RCC, eosinophilic	Solid and uniform architecture, irregular nuclear membranes, perinuclear halos	CD117$^+$, CK7$^+$, CK20$^-$
Oncocytoma	Uniform cytology, lacks macrocysts	CD117$^+$, CK7 $^{-/+}$, CK20$^-$
Epithelioid angiomyolipoma	Epithelioid cells that may be pleomorphic, lacks macrocysts	PAX8$^-$, HMB45$^+$, PanCK$^-$, CK7$^-$, CK20$^-$
Papillary RCC, oncocytic	Papillary formations (at least focal), uniform cytology	CK7$^+$, CK20$^-$
Clear cell RCC, eosinophilic morphology	Focal clear cell areas, delicate vasculature, may contain macrocysts	CA9$^+$, CK20$^-$
MiT translocation RCC	Large cells with clear (or eosinophilic) morphology, focal papillary and nested growth, lack cysts (usually)	TFE3$^+$, TFEB$^+$, HMB45$^+$, PanCK$^-$
SDH-deficient RCC	Lacks macrocysts, uniform low-grade oncocytic cells with flocculent to densely eosinophilic cytoplasmic vacuoles	CD117$^-$, SDHB$^-$, SDHA$^+$, CK20$^-$

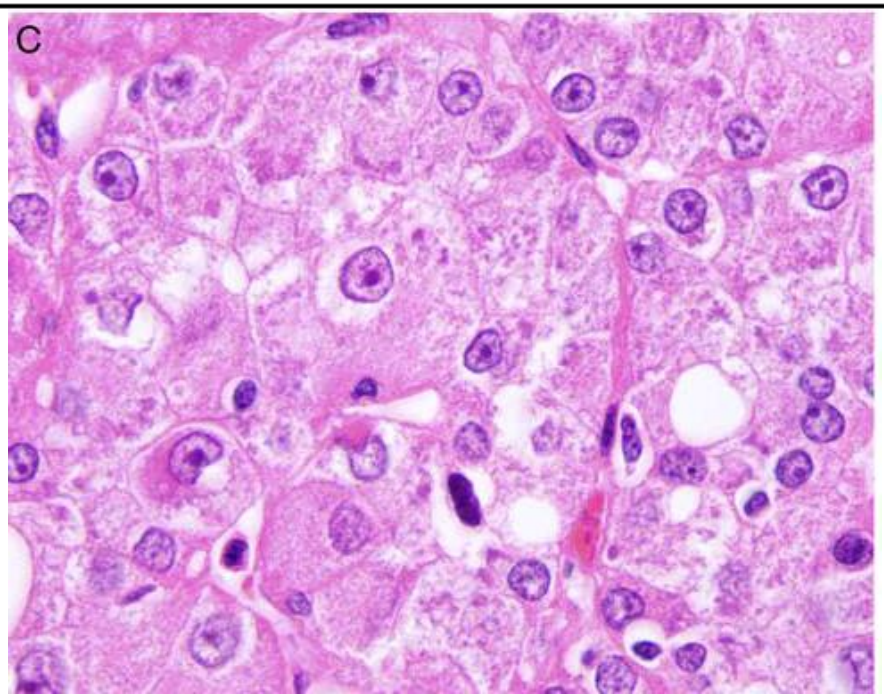

Trpkov 2017

part 2

Pr Hes

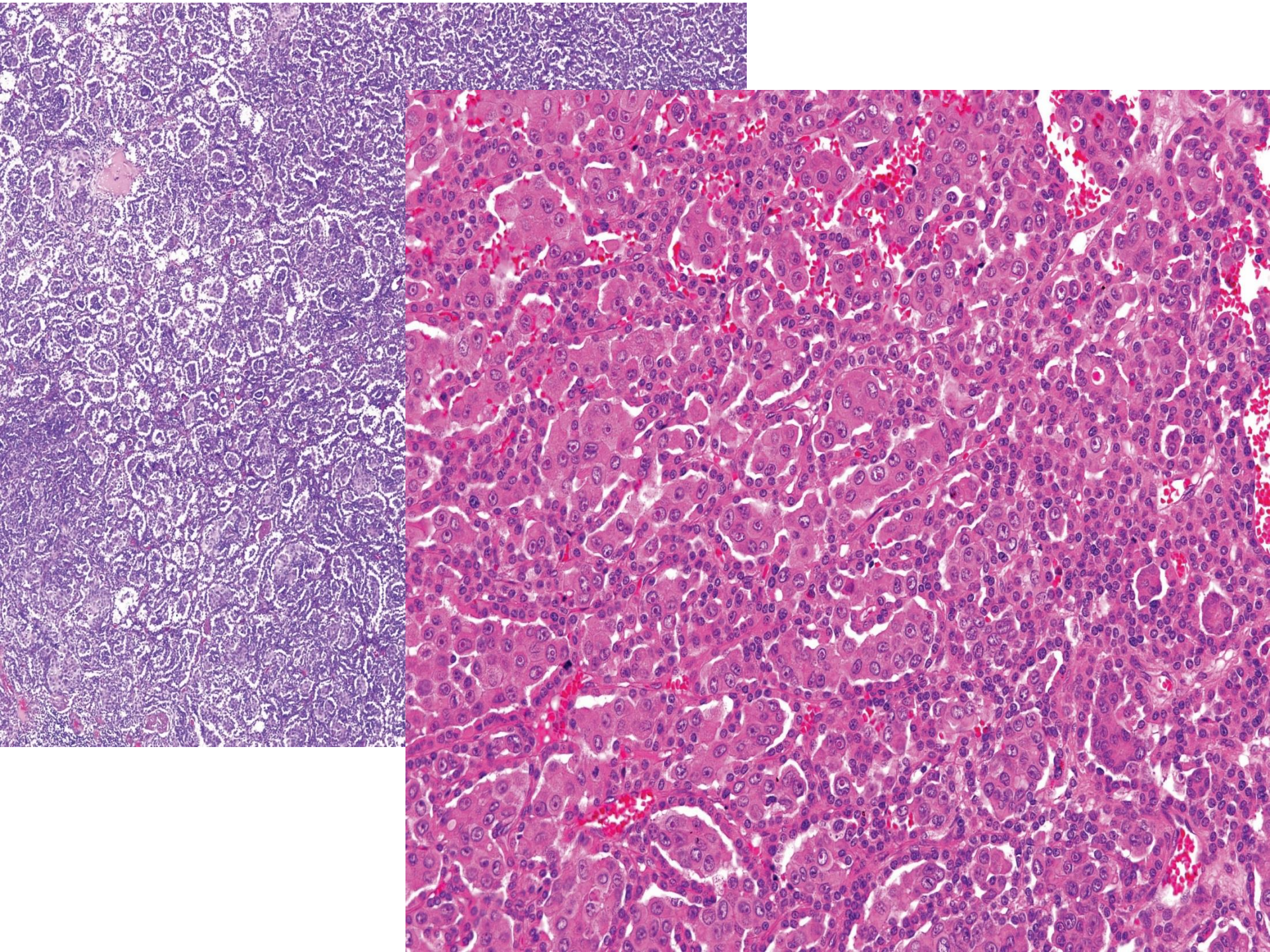

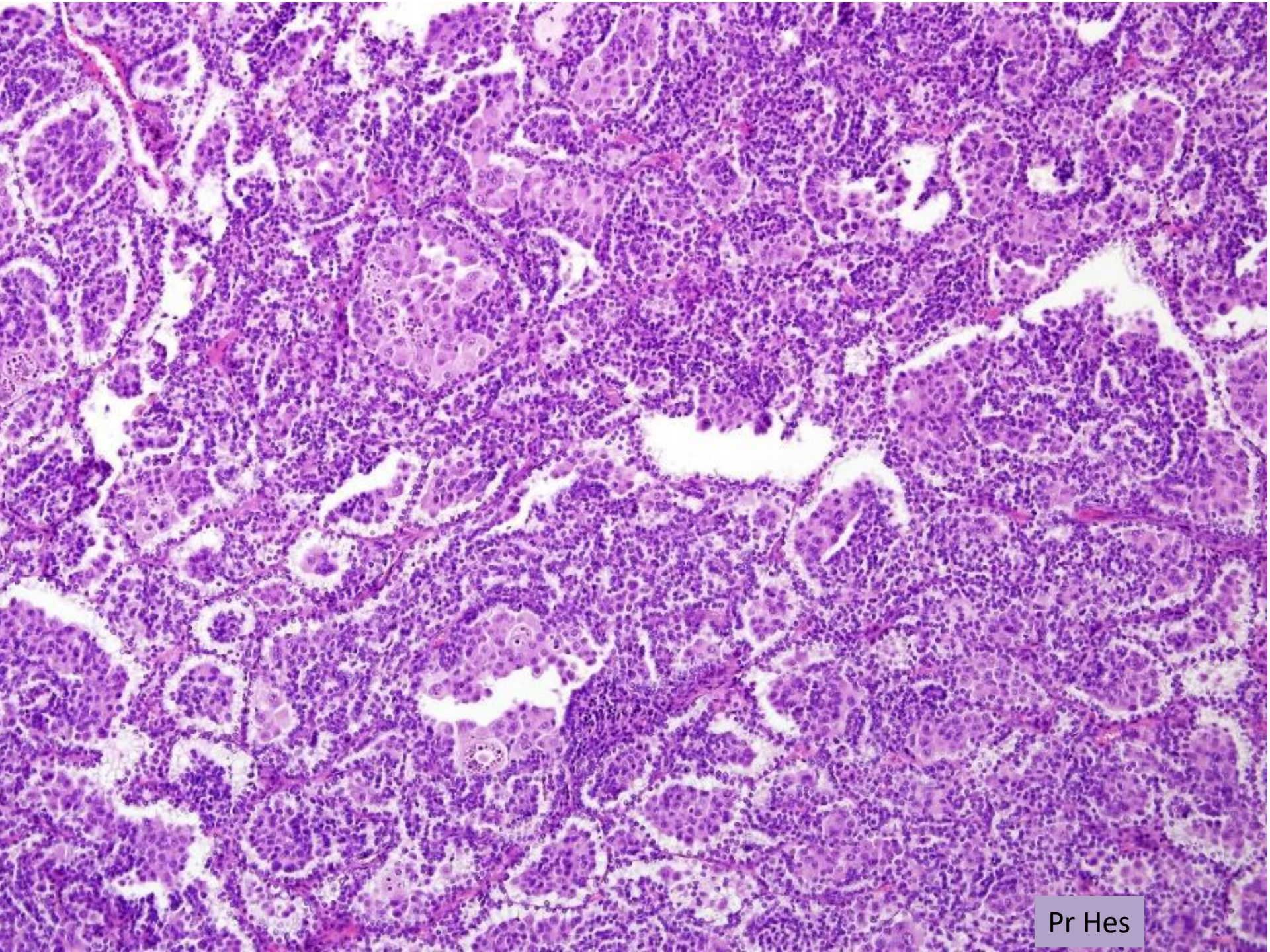
Pr Hes

Biphasic squamoid alveolar RCC (BSARCC)

- first description 2012

Biphasic alveolosquamoid renal carcinoma: a histomorphological, immunohistochemical, molecular genetic, and ultrastructural study of a distinctive morphologic variant of renal cell carcinoma☆,☆☆

Fredrik Petersson, MD, PhD[a,b], Stela Bulimbasic, MD, PhD[c], Ondrej Hes, MD, PhD[a,*], Pavol Slavik, MD[d], Petr Martínek, MSc[a], Michal Michal, MD[a], Barbora Gomolčáková[e], Milan Hora, MD, PhD[f], Ivan Damjanov, MD, PhD[g]

- différentiation squamoide
- arrangement alvéolaire
- pas de transformation sarcomatoide
- 0,1% dans population générale

clinique

- unifocale ou bilatérale/multifocale++
- âge 39-79 ans
- distribution H=F dans les cas sporadiques
- taille 1,5- 16cm

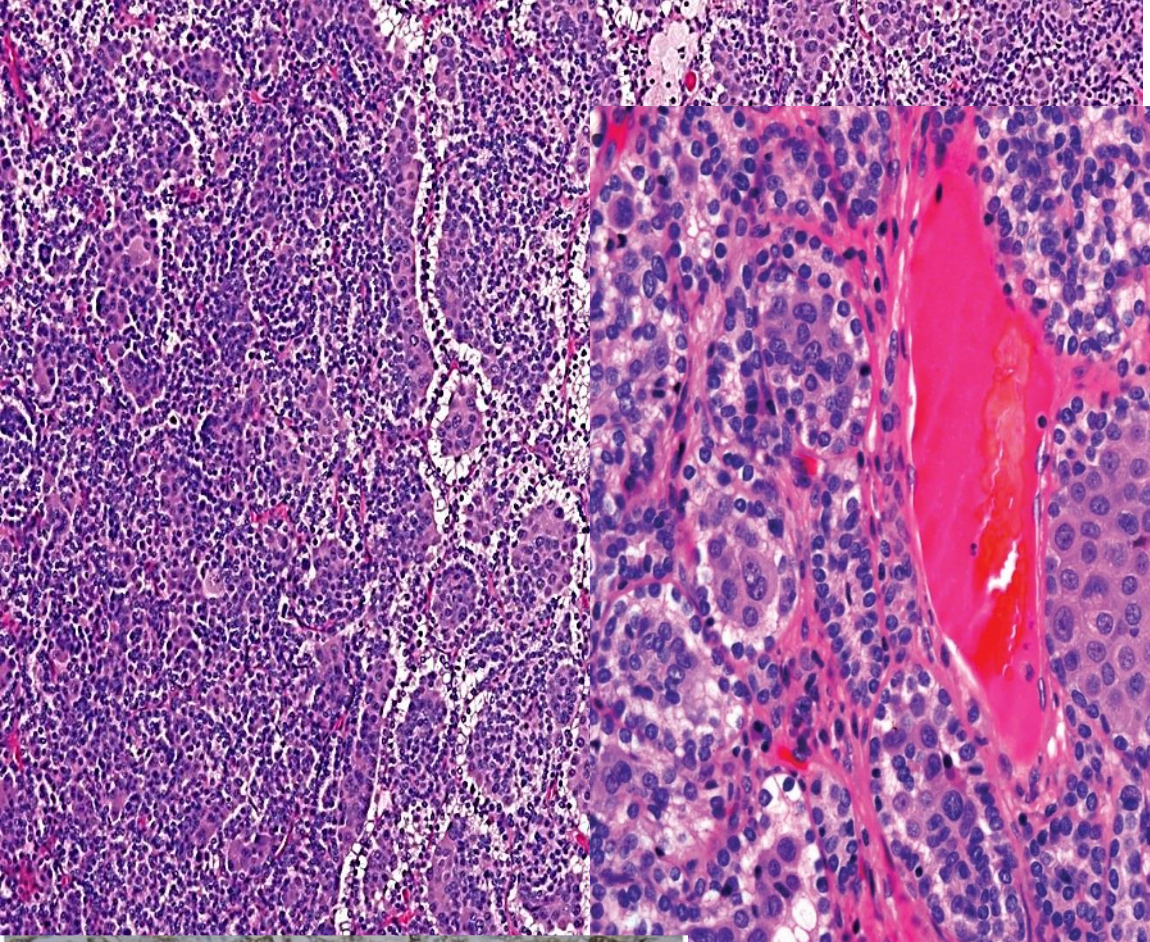

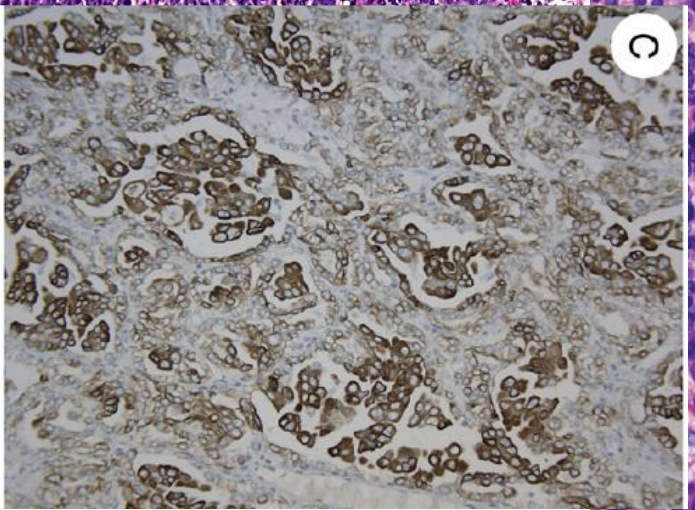

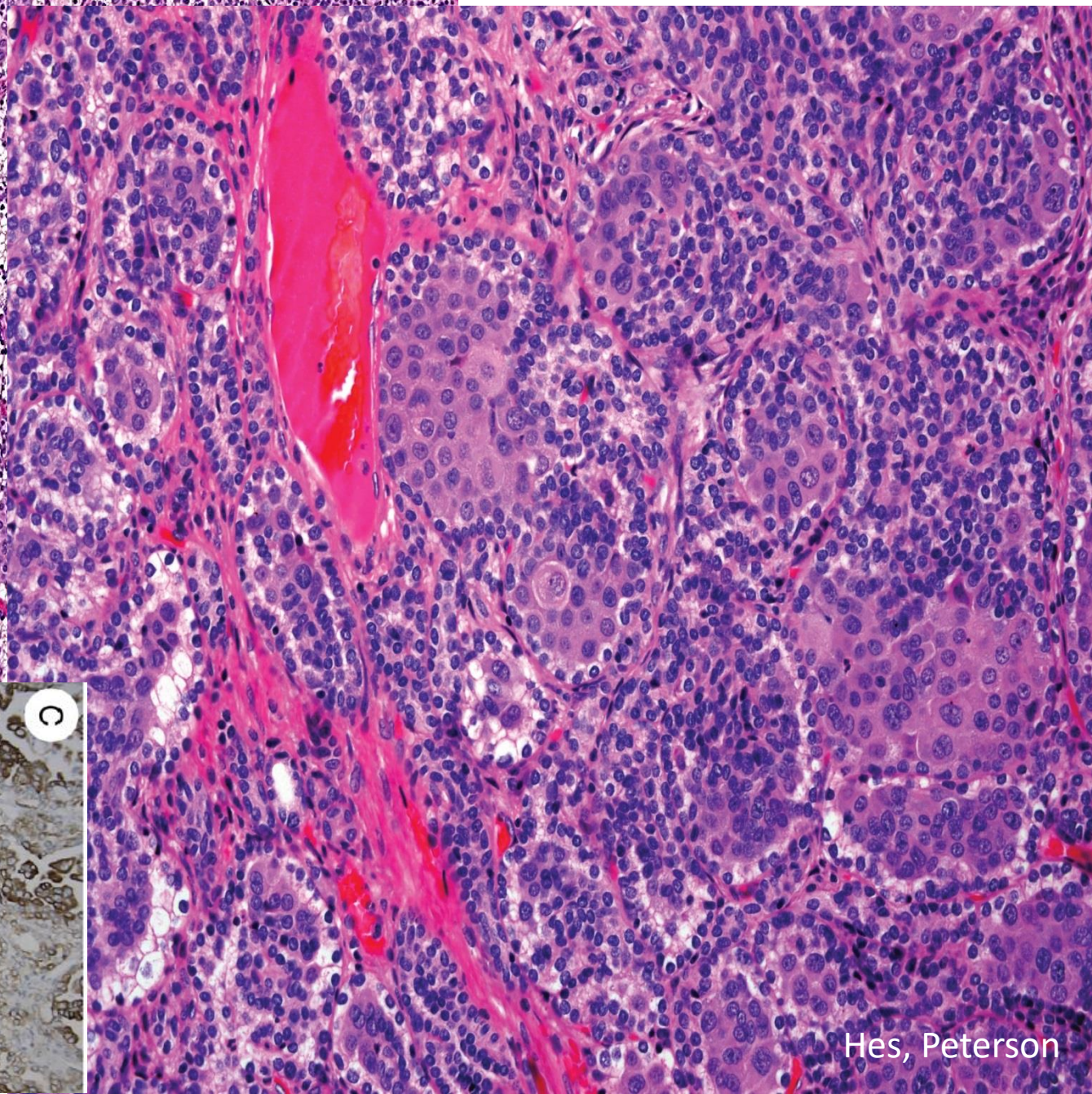

Hes, Peterson

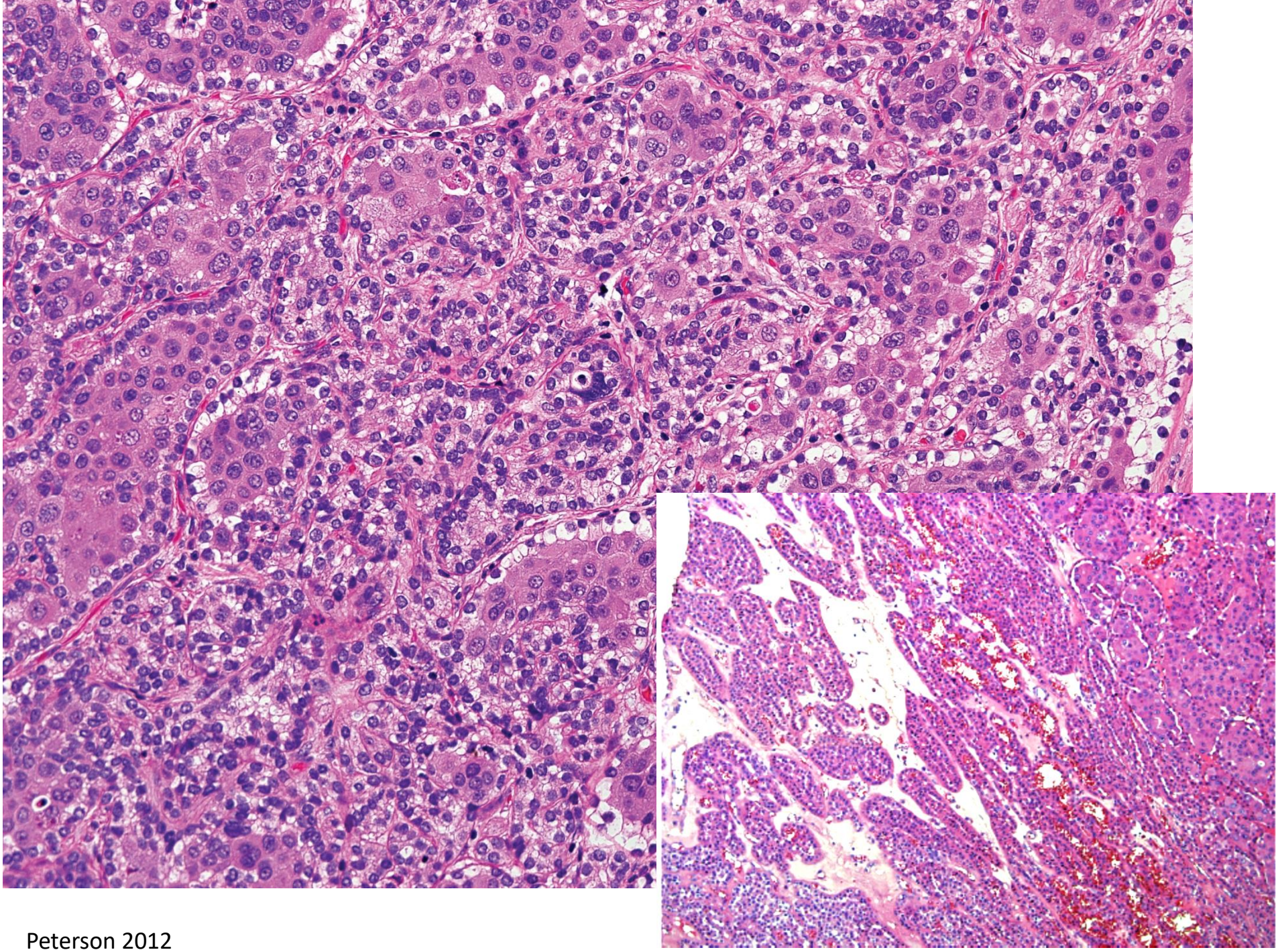

Peterson 2012

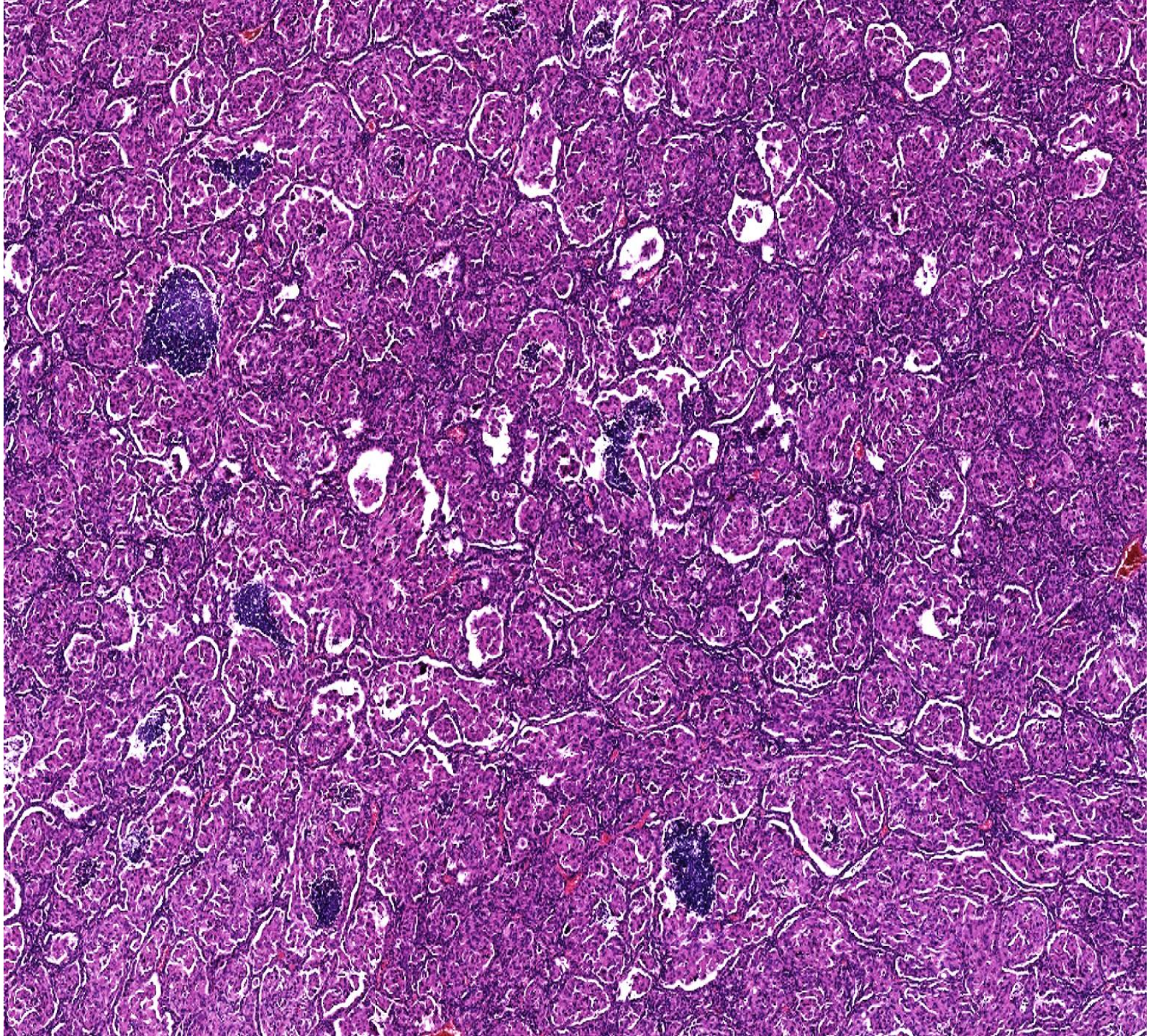

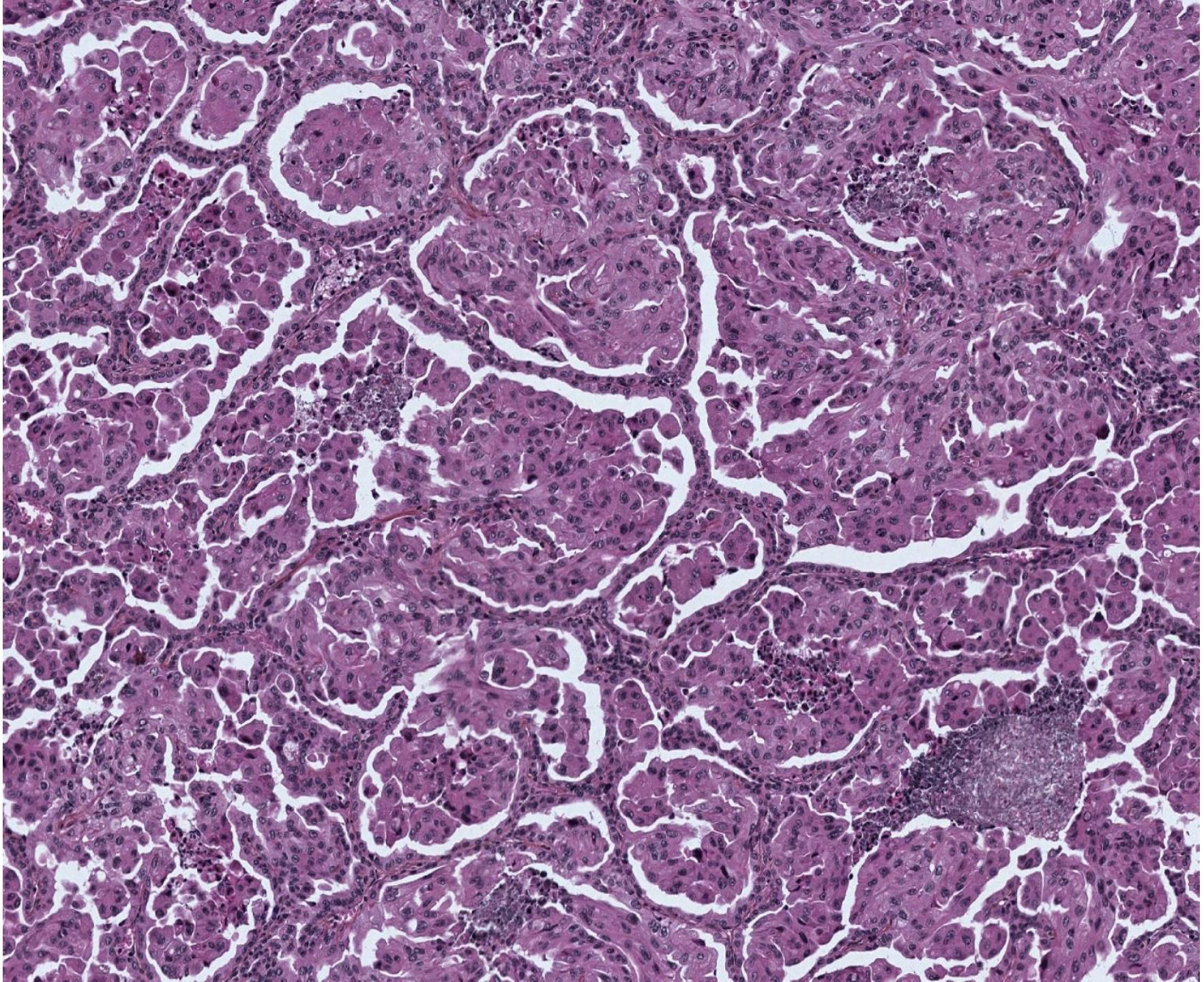

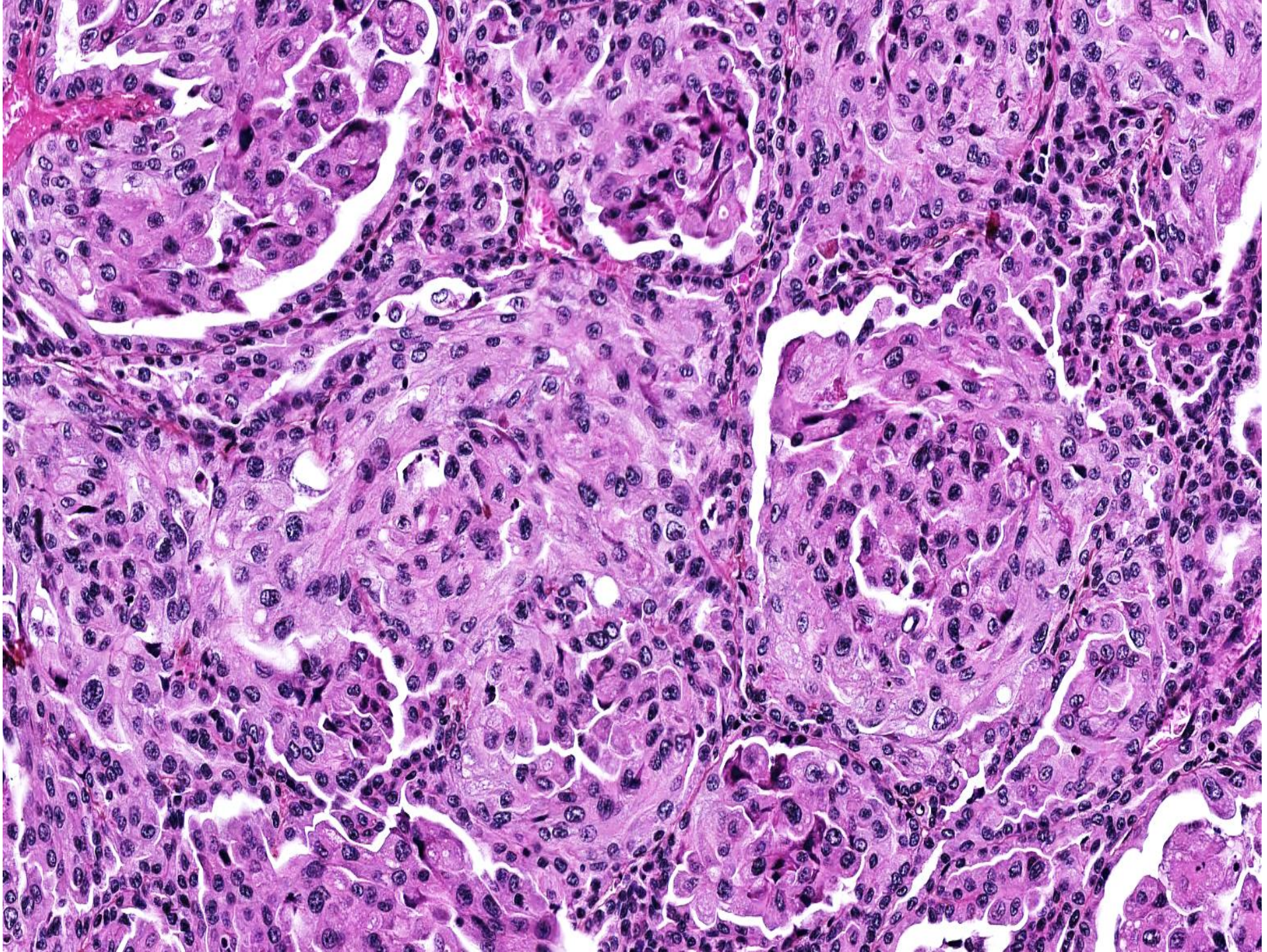

IHC

- **100% +**
  - CK7+, EMA, vimentine, p504s
  - cyclin-D1 (grandes cellules squamoides)
- **100% -**
- CA9, CD117, GATA3, WT1, CK5/6, CK20
- **+/-**
  - CD10, 34βE12

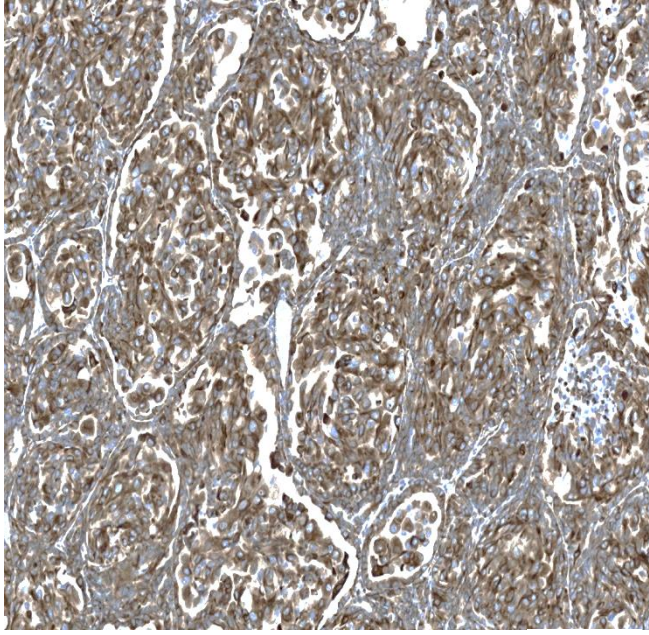

CK7

PAX8

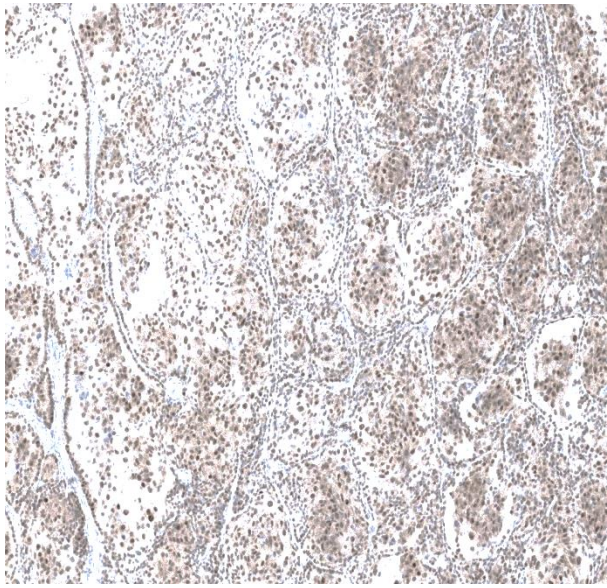

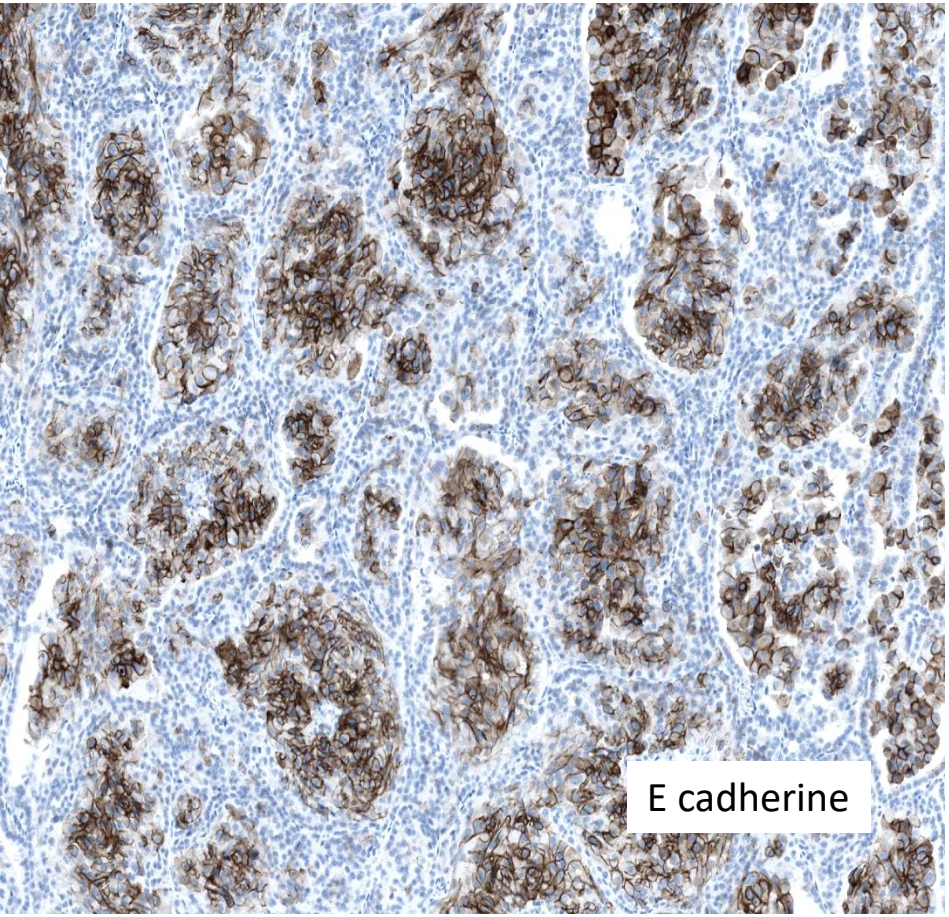
E cadherine

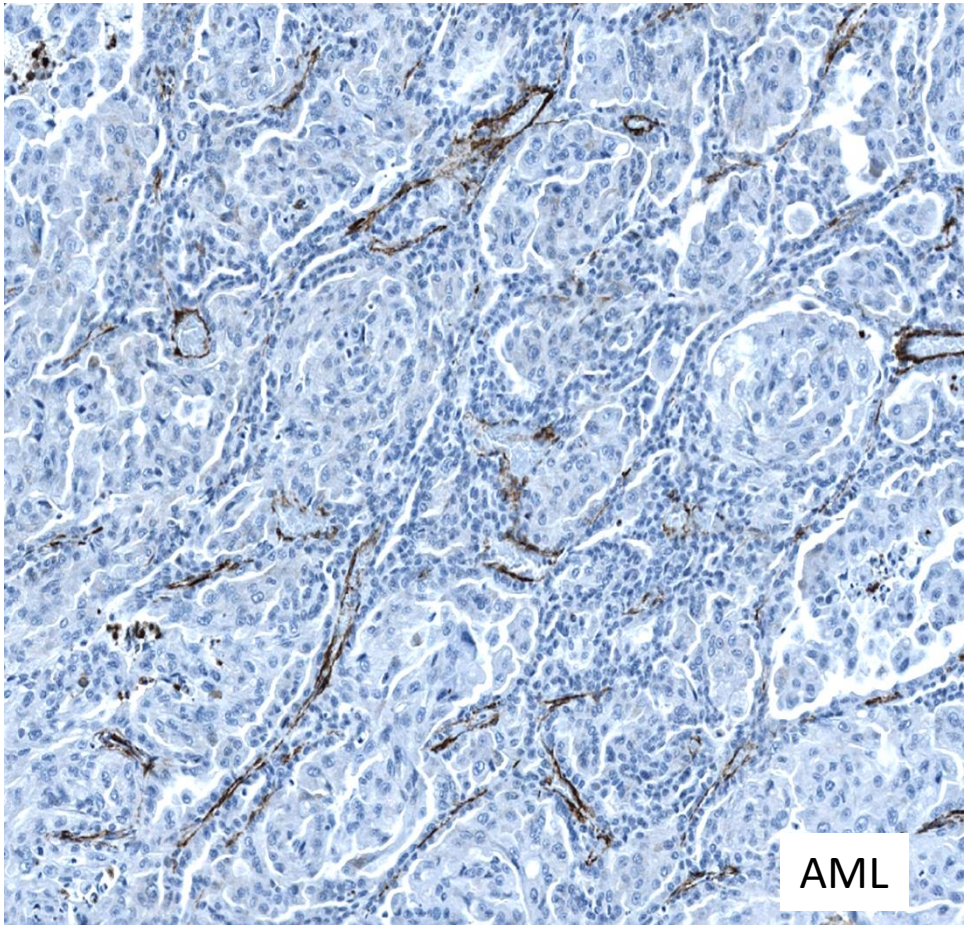
AML

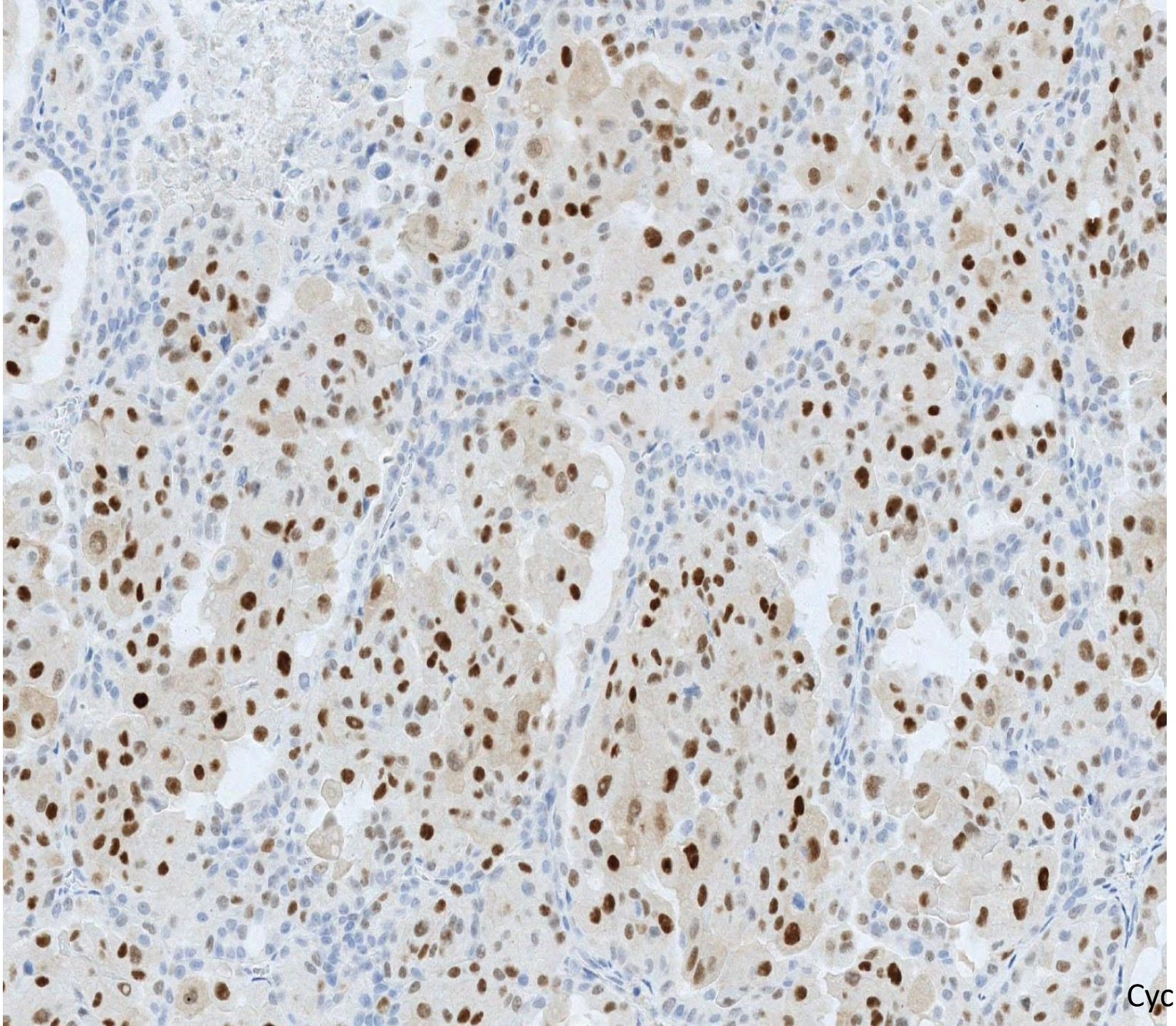

Cyclin D1

clinique

- jusqu'à 15% aggressives
  - récidives, M+, décès
- génétique
  - trisomies 7,17, perte Y
- transition entre 2 composantes
- variante de ca papillaire?
  - cas héréditaires
  - ca papillaire héréditaire, *MET* mutation
  - mélange de ca papillaire et BSARCC

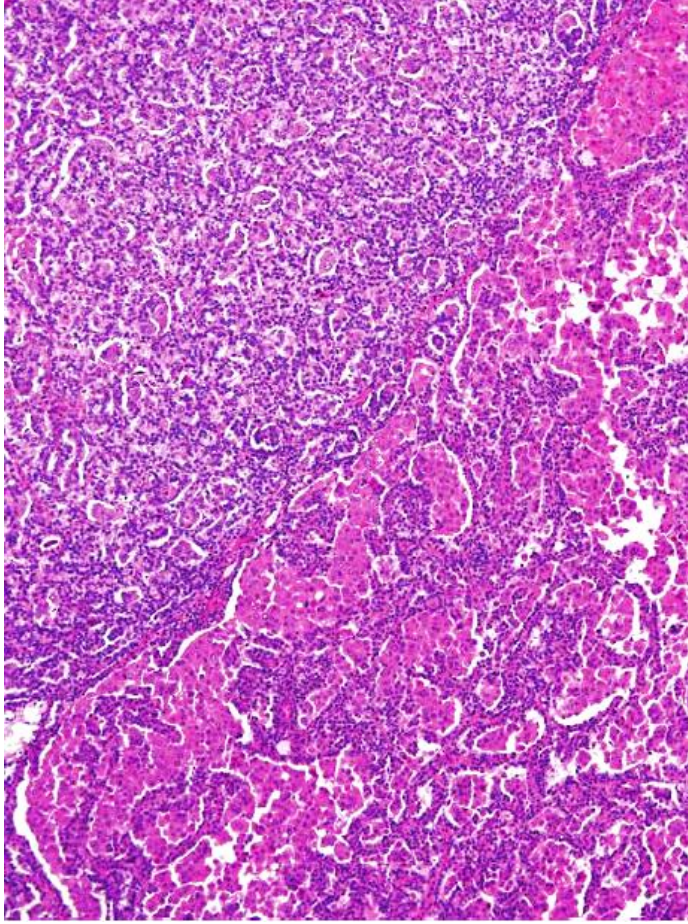

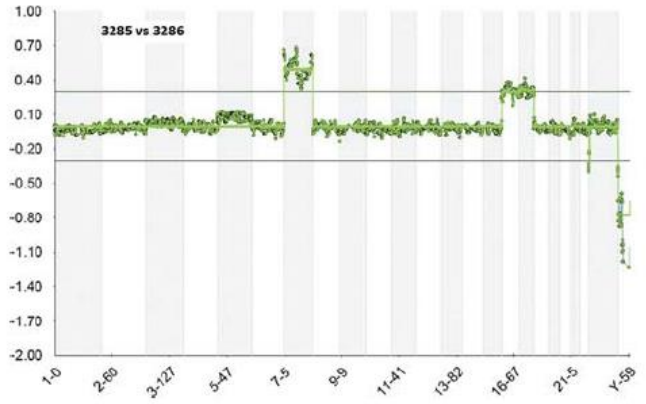

Hes, AJSP 2016, Chartier AJSP 2018

cas malignes

- psammomes
- aspects plus solides avec squamoides cellules

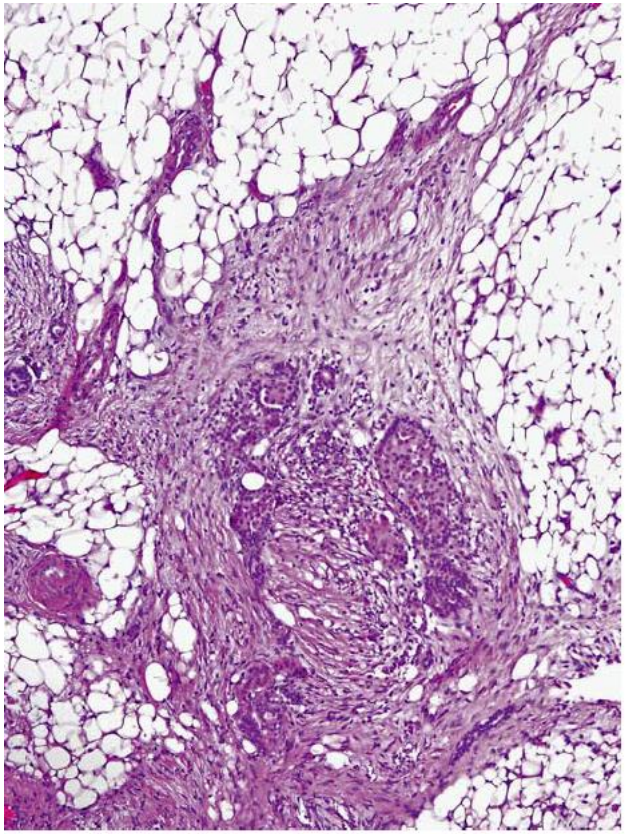

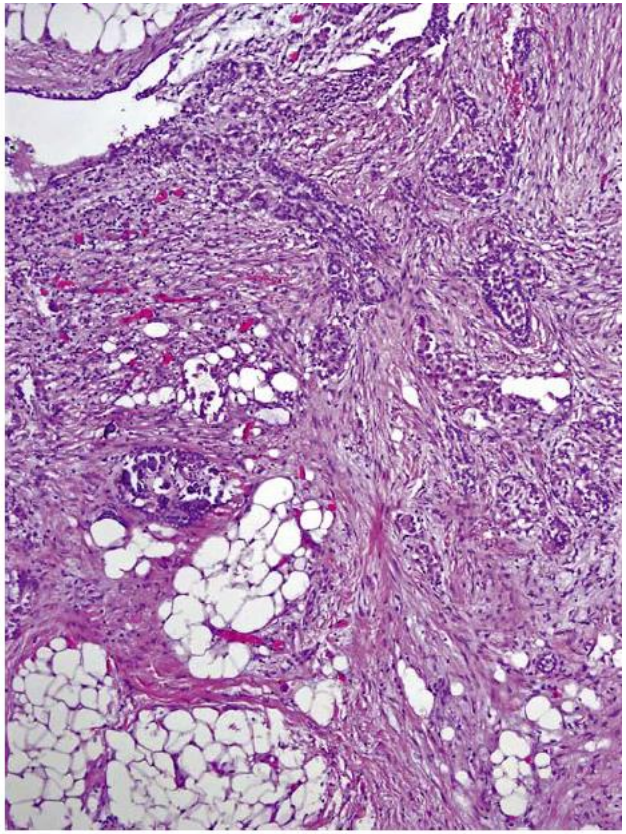

Renal cell carcinoma in kidney allografts: histologic types, including biphasic papillary carcinoma ☆

Megan L. Troxell MD, PhD[a,b,*], John P. Higgins MD[a]

- tumeurs d'allogreffes
  - 0,26%
  - 50% ca papillaires dont 1/3 BSARCC (sur toute série 16%)
  - pas de récurrence
  - pas de M+
  - bien limités
  - pT1
  - emperiopolesis

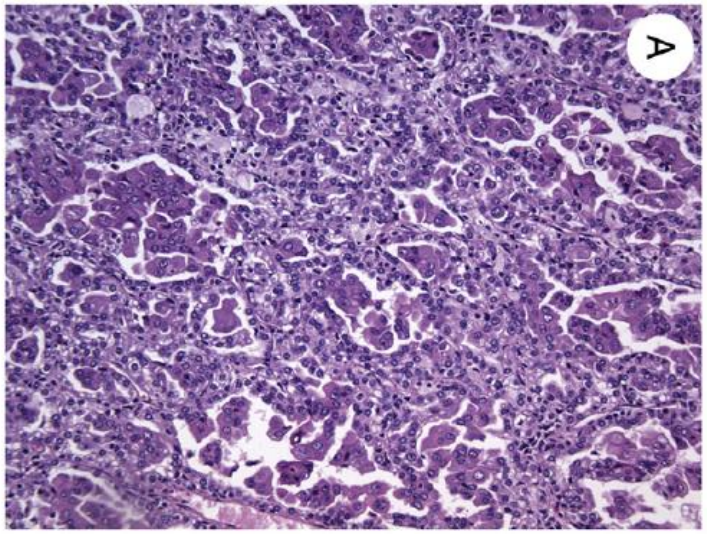

Hum Path 2016

Biphasic Squamoid Alveolar Renal Cell Carcinoma

A Distinctive Subtype of Papillary Renal Cell Carcinoma?

Ondrej Hes, MD, PhD, Enric Condom Mundo, MD, PhD,†‡ Kvetoslava Peckova, MD,* Jose I. Lopez, MD,§ Petr Martinek, PhD,* Tomas Vanecek, PhD,* Giovanni Falconieri, MD,‖ Abbas Agaimy, MD,¶ Whitney Davidson, MD,# Fredrik Petersson, MD, PhD,** Stela Bulimbasic, MD, PhD,†† Ivan Damjanov, MD, PhD,# Mireya Jimeno, MD,‡‡ Monika Ulamec, MD, PhD,§§ Miroslav Podhola, MD, PhD,‖‖ Maris Sperga, MD,¶¶ Maria Pane Foix, MD,†‡ Ksenya Shelekhova, MD, PhD,## Kristyna Kalusova, MD,*** Milan Hora, MD, PhD,*** Pavla Rotterova, MD, PhD,* Ondrej Daum, MD, PhD,* Kristyna Pivovarcikova, MD,* and Michal Michal, MD**

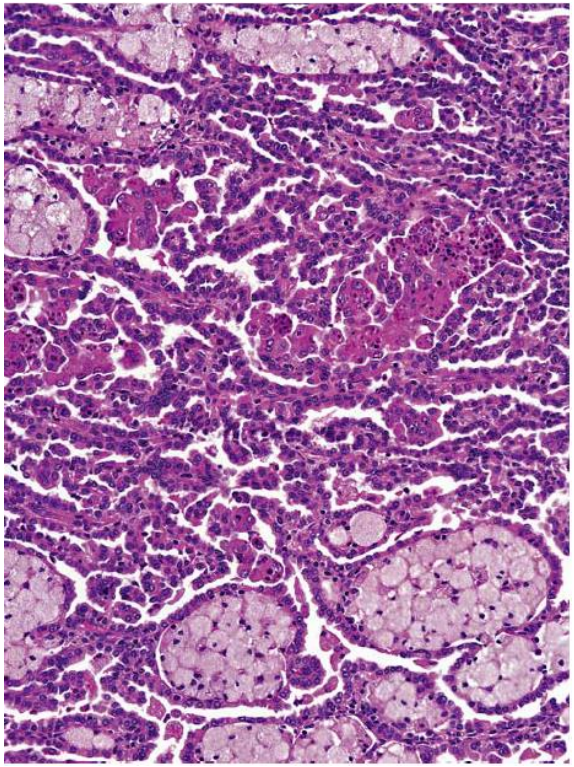

- deux populations de cellules
- cellules squamoides 10-80% de la surface
  - nucleoli proéminents
  - nids compactes
- cellules tumorales de bas grade bordant structures alvéolaires
- cellules spumeuses
- transition entre zones alvéolaires et compactes
- emperiopolesis dans tous les cas

HES AJSP 2016

emperiopolesis

- définition
  - l'emperipolesis est la présence d'une cellule intacte dans le cytoplasme d'une autre cellule
  - l'emperipole est un processus biologique peu commun et peut être physiologique ou pathologique. Elle est liée à la péripoleis, qui est l'attachement d'une cellule à une autre
  - la cellules reste viable
  - c.f. maladie du Rosai-Dorfman

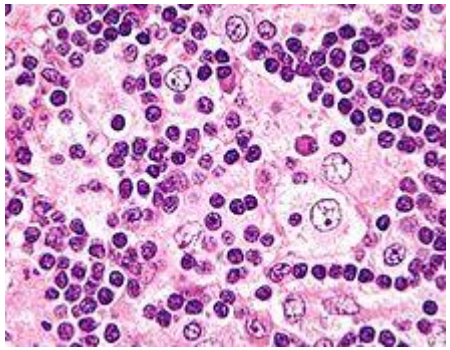

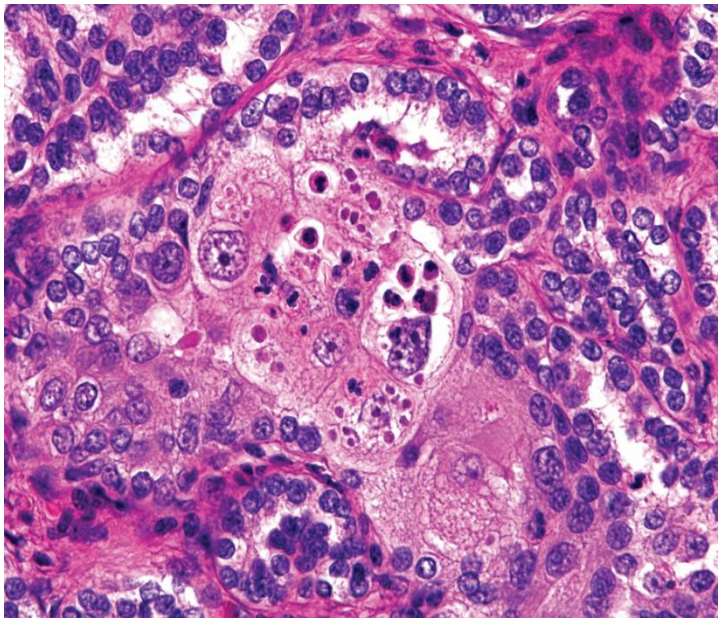

High-grade renal cell carcinoma with emperipolesis: Clinicopathological, immunohistochemical and molecular-genetic analysis of 14 cases

Pavla Rotterova[1,2], Petr Martinek[1], Reza Alaghehbandan[3], Kristyna Prochazkova[4], Ivan Damjanov[5], Joanna Rogala[6], Saul Suster[7], Delia Perez-Montiel[8], Isabel Alvarado-Cabrero[9], Maris Sperga[10], Marian Svajdler[1], Kvetoslava Michalova[1], Kristyna Pivovarcikova[1], Ondrej Daum[1], Milan Hora[4], Martin Dusek[1], Ondrej Ondic[1], Adela Stehlikova[1], Michal Michal[1] and Ondrej Hes[1,11]

- peut aussi être observé dans carcinomes rénaux
- à cellules claires de haut grade, ISUP 4
- rarement dans carcinomes papillaires
- CA9+
- indicateur de mauvais pronostic

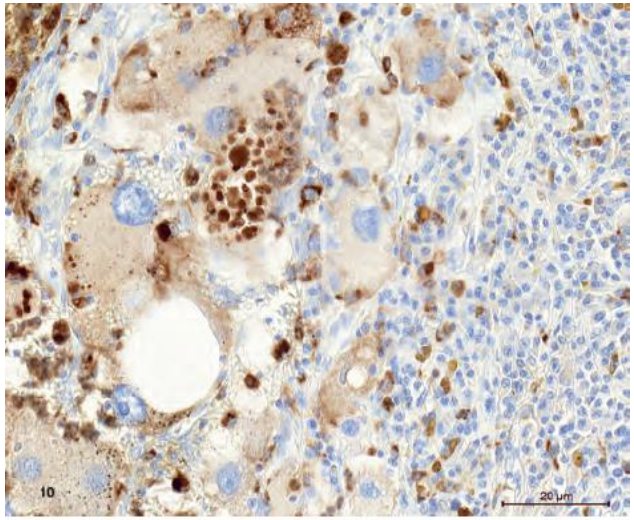

Fig. 10. CD68 was positive in large bizarre cells with emperipolesis. Positivity was strong and mostly cytoplasmic. x 200

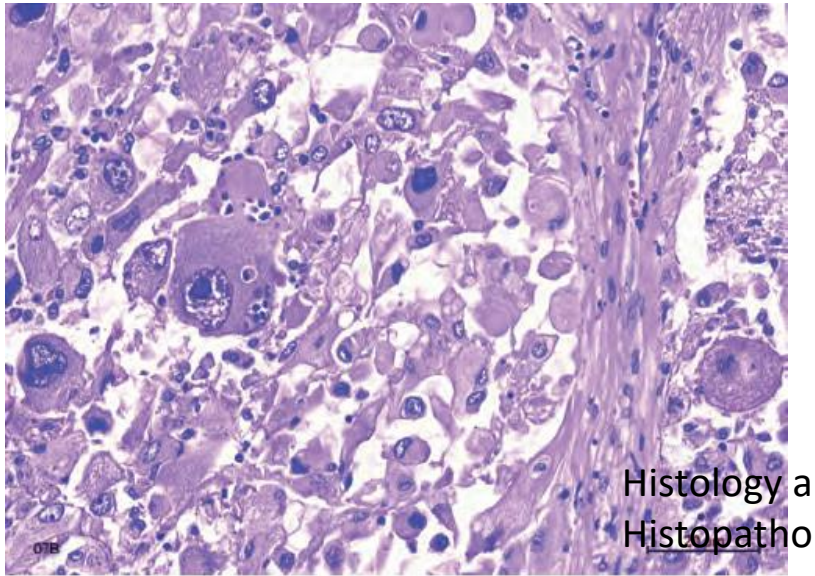

Histology and Histopathology 2018

DD

- carcinome urothélial avec différentiation épidermoïde
  - mais BSARCC se développe dans parenchyme rénal
  - pas de relation avec urothélium

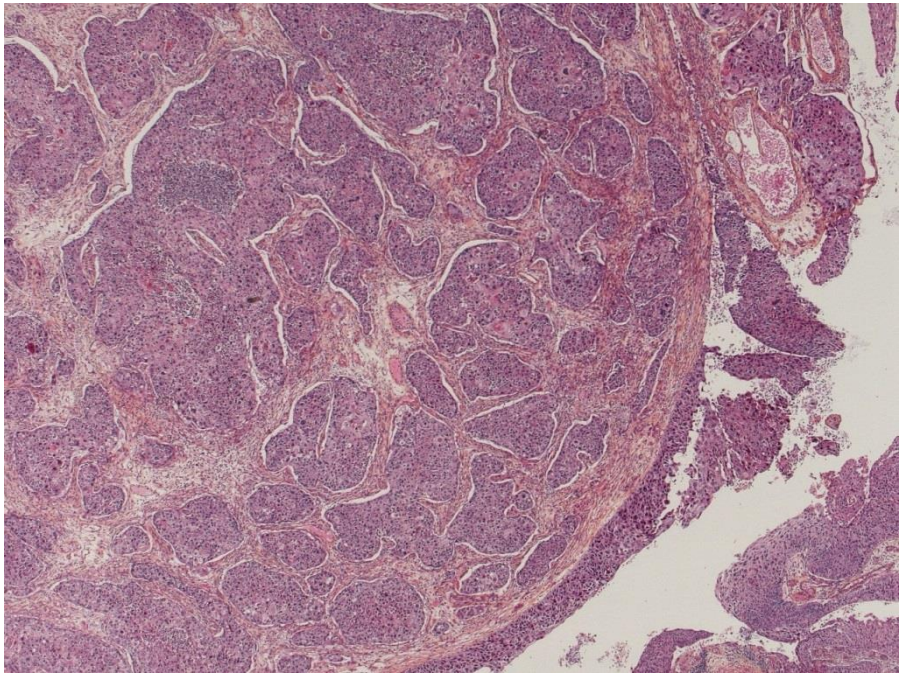

conclusion

- imprévisible quelle entité sera dans prochaine OMS
- certaines entités avec profil
  - clinique
  - morphologiques
  - immunohistochimiques
  - génétiques
  - bien définis
- à reconnaitre car assez particulier